كلية التمريض
SCHOOL OF NURSING

Health Promotion of the Newborn and Family

Chapter 7

كلية التمريض
SCHOOL OF NURSING

Objectives

By the end of this discussion you will be able to:

- Define the normal neonatal infant
- Explain the immediate adjustment to extra uterine fetal life
- Discuss the fetal circulation and neonatal circulation

Omayah Nassar PN, PhD, CPT
Sumaia Halasa, RN, PhD, CIMI, CPT

Normal Neonatal Infant

Newborn:

- From second stage of labor till 72 hours after birth

Neonate:

- The first month of life

Omayyah Nassar, PN, PhD, CPT
Suhaila Halaseh, RN, PhD, CIMI

https://www.dreamstime.com/stock-photo-newborn-baby-girl-image19302470

Normal Neonatal Infant

- **Term (-- - --)**
- **AGA**
- **Normal A/S**
- **N- C-n-e-i-al –n-m-l-e-**

Omayah Nassar, PN, PhD, CPT
Suhaila Halasa, RN, PhD, CPT

https://www.dreamstime.com/stock-photo-newborn-baby-girl-image19302470

Normal Neonatal Infant

- **Term:** (38-42), or 40 + or – 2 gestational weeks
  - Full term: 40 weeks of gestation
- **AGA:** Appropriate for Gestational Age (2.5kg-4.5kg), average: 3.5kg
- **Normal A/S (7/10)**
- **No Congenital Anomalies**

Omaya Nassar, PN, PhD, CPT
Suhaila Halasa, RN, PhD, CIMI, CPT

Introduction

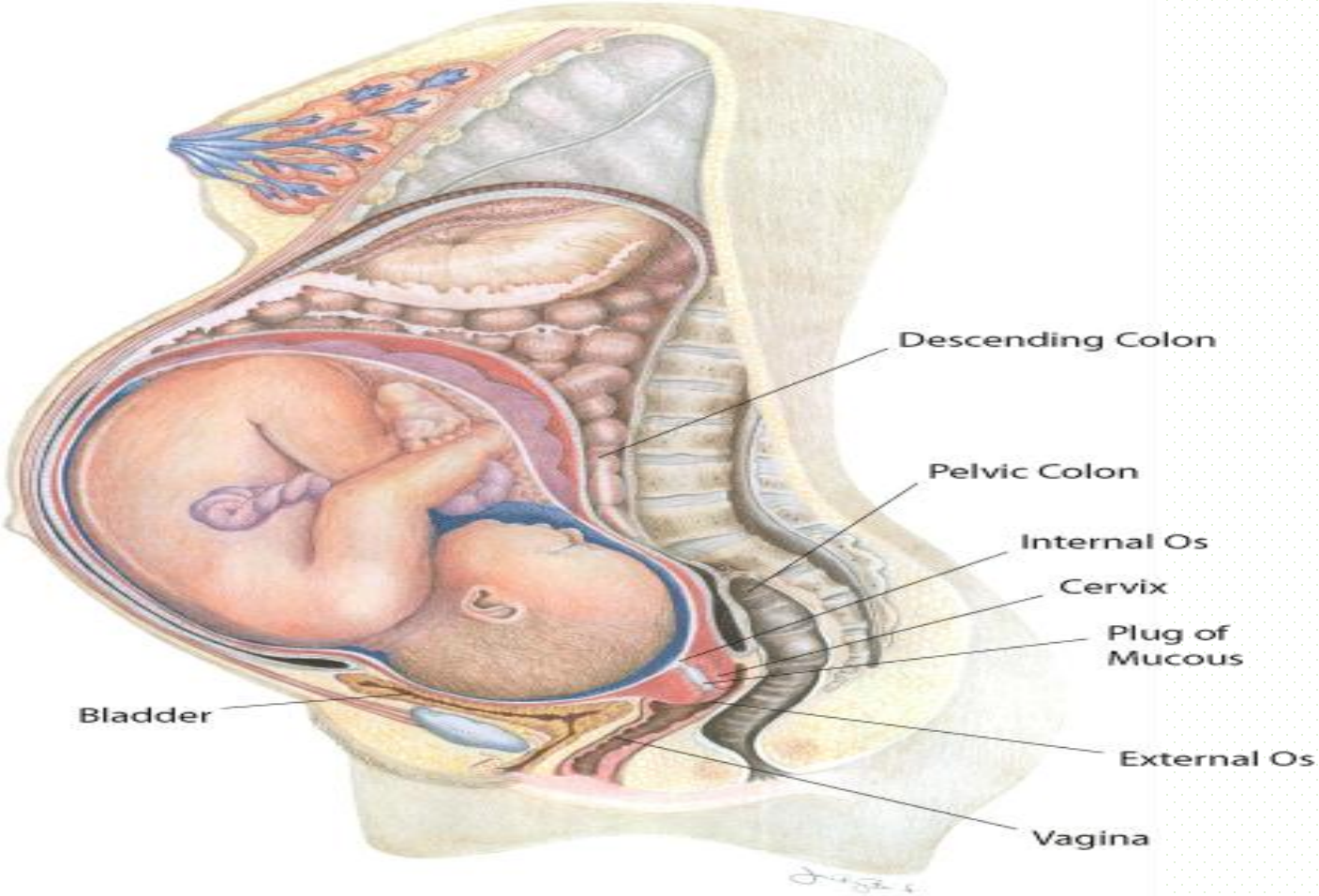

https://www.anatomynote.com/human-anatomy/infant-child-anatomy/pregnant-woman-sectional-view-with-infant-in-uterus/

كلية التمريض
SCHOOL OF NURSING

Introduction

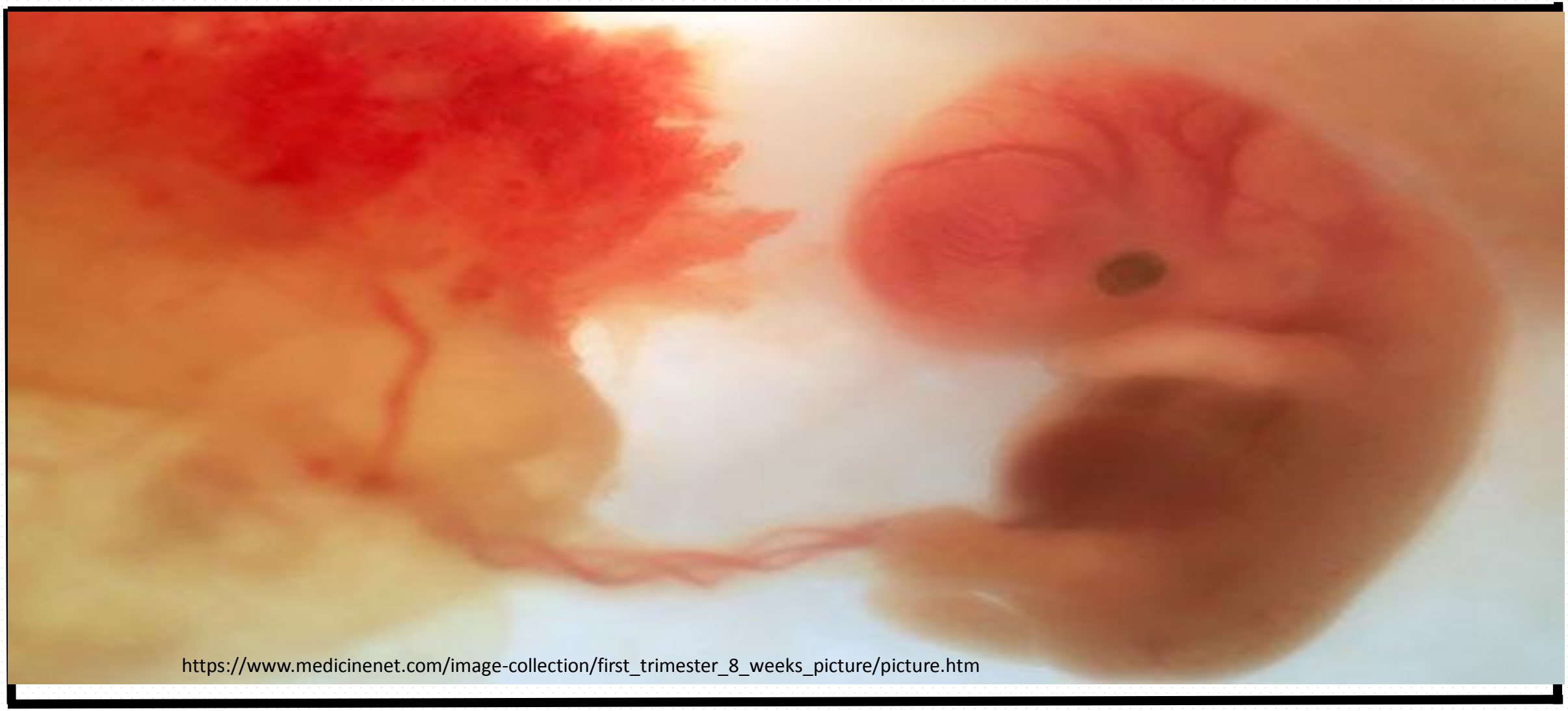

https://www.medicinenet.com/image-collection/first_trimester_8_weeks_picture/picture.htm

Birth Weight Related to Gestational Age

- Birth weight alone is a poor indicator of gestational and fetal maturity
- Gestational age reflects fetal maturity
- Intrauterine growth charts are used to classify the infant and help identify one at risk

Omayah Alassar, PN, PhD, CPT
Suhaila Halasa, RN, PhD, CIMI, CPT

Birth Weight Related to Gestational Age

- Appropriate for gestational age (AGA):

  Growth between the 10th and 90th percentiles

- Small for gestational age (SGA):

  Below the 10th percentile

- Large for gestational age (LGA):

  Above the 90th percentile

Omayah Hassar, PN, PhD, CPT
Sumaia Halasa, RN, PhD, CNM, CPT

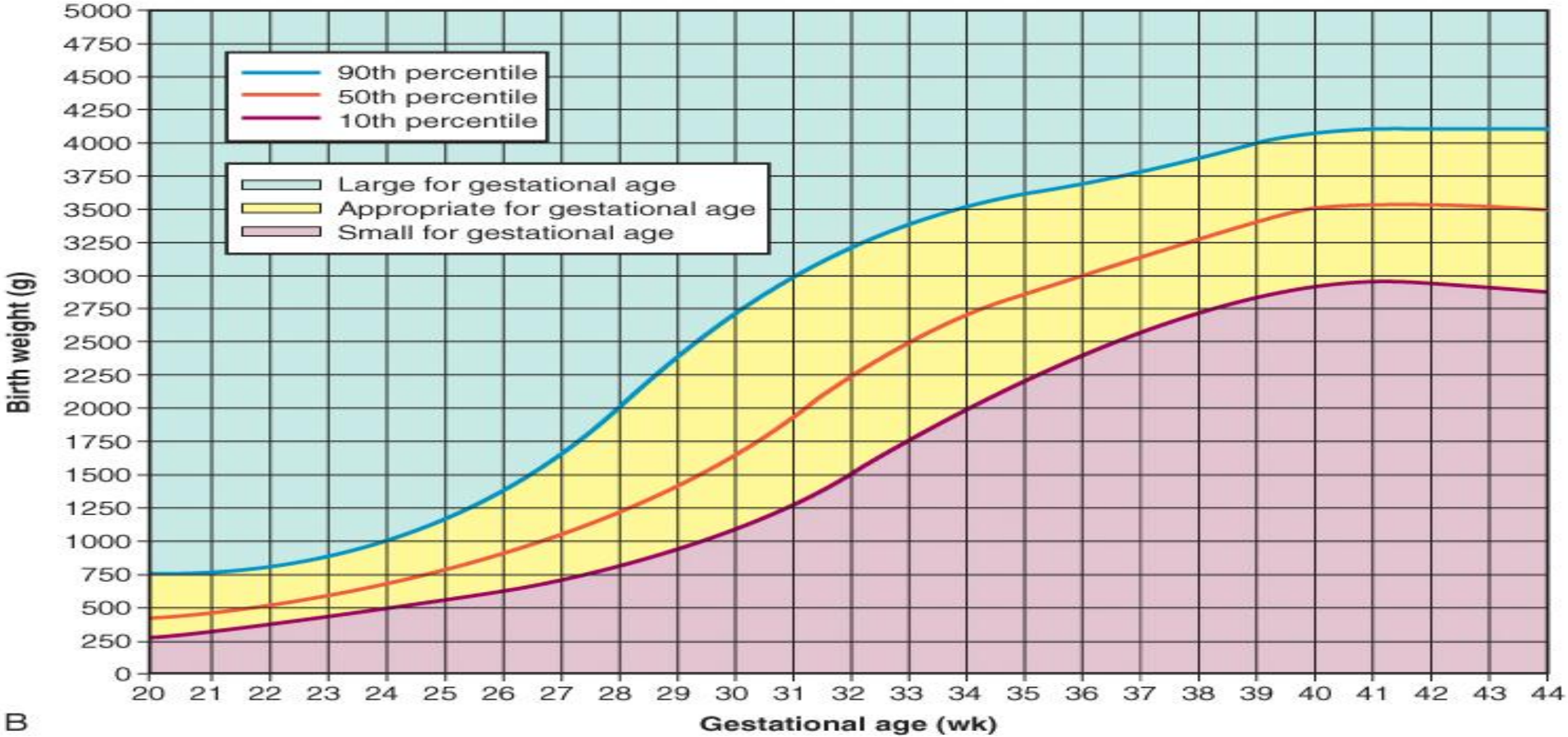

FIG 8-1B A, New Ballard Scale for newborn maturity rating. Expanded scale includes extremely preterm infants and has been refined to improve accuracy in more mature infants. **B,** Intrauterine growth: birth weight percentiles based on live single births at gestational ages 20 to 44 weeks.

Data from Alexander GR, Himes JH, Kaufman RB, and others: A United States national reference for fetal growth, *Obstet Gynecol* 87[2]:163–168, 1996.

IG 8-2 Three infants, same gestational age, weight 600, 1400, and 2750 g, respectively, from left to right.

From *Perinatal assessment of maturation*, National Audiovisual Center, Washington, DC.

Apgar Scoring System

Sign	0	1	2
Heart rate	Absent	<100 beats per minute	>100 beats per minute
Respiratory effort	Absent	Irregular; slow, weak cry	Good; strong cry
Muscle tone	Limp	Some flexion	Well flexed
Response	No response	Grimace	Cry, sneeze
Color	Blue, pale	Body pink, extremities blue	Completely pink

nayah Nassar, PN, PhD, CI
uhaila Halasa, RN, PhD, CIMI, CPT

كلية التمريض
SCHOOL OF NURSING

Immediate Adjustment to extra uterine life

Introduction

* Respiratory System
* Circulatory System
* Gastro Intestinal System
* Renal System

Omayah Nassar, PN, PhD, CPT
Sumaia Halasa, RN, PhD, CIMI, CPT

كلية التمريض
SCHOOL OF NURSING

Immediate Adjustment to Extra uterine Life

- **The most important physiological change is the transition from fetal or placental circulation independent respiration**

- **Loss of placental connection with the fetus means:**

- Loss of complete metabolic support esp. the supply of oxygen and the removal of carbon dioxide

- Increase incidence of fetal Asphyxia

Omayah Nassar, PN, PhD, CPT
Suhaila Hamsa, RN, PhD, CHMI, CPT

كلية التمريض
SCHOOL OF NURSING

Dose every newborn experiences the incidence of Asphyxia?

https://www.medicinenet.com/image-collection/third_trimester_36_weeks_picture/picture.htm

The stress of labor and delivery

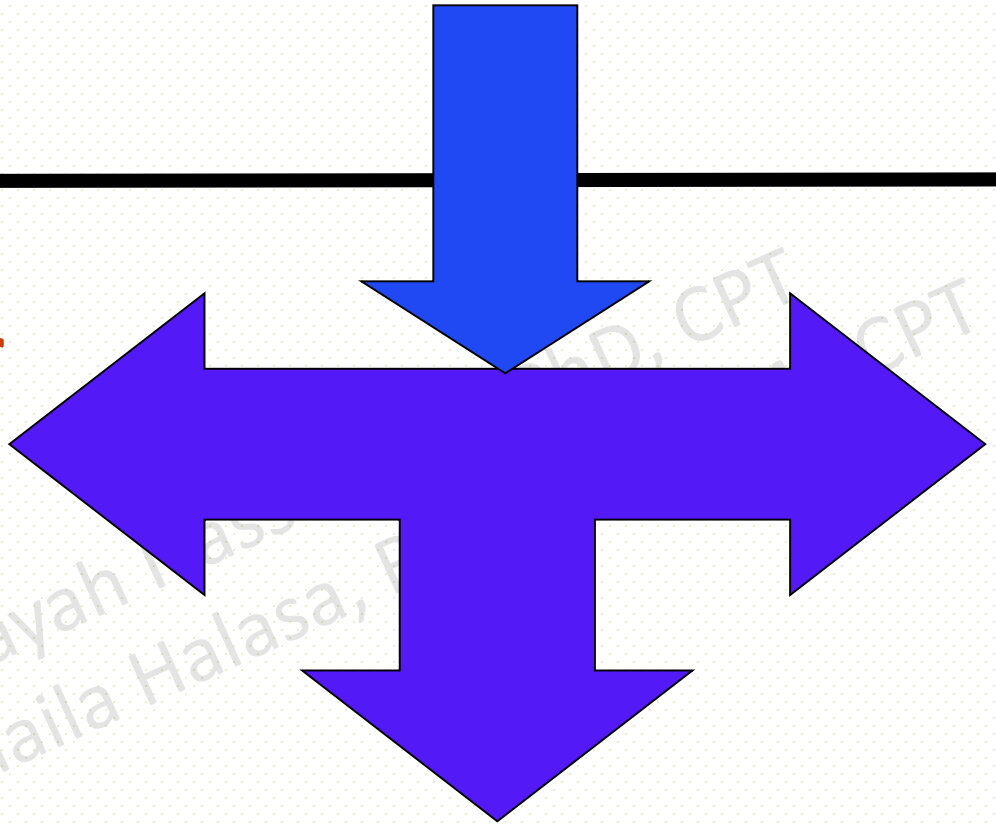

Cardiovascular activity

Acid- base balance in the blood

Alteration of placental Gas exchange patterns

Omayah Hass... PhD, CPT
Suhaila Halasa, P... CPT

كلية التمريض
SCHOOL OF NURSING

What do you think ????

- **The stress of labor & Delivery**
    1. Alteration of placental affects Gas exchange patterns
    2. Acid- base balance in the blood
    3. Cardiovascular activity

Omayah Nassar PN, PhD, CPT
Suhaila Halasa RN, PhD, CHWL CPT

Neonatal Asphyxia

Immediate Adjustments

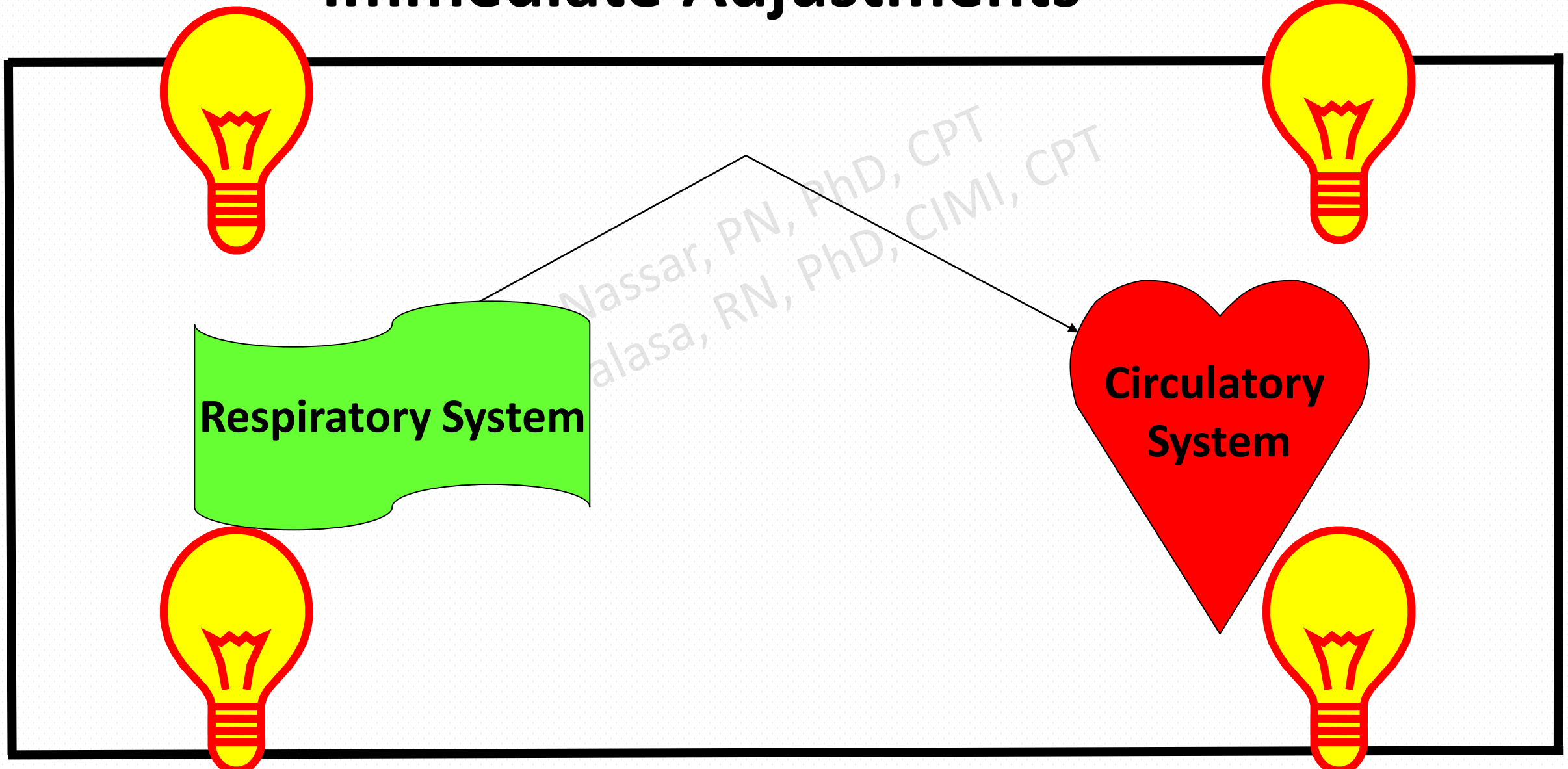

Nassar, PN, PhD, CPT
Alasa, RN, PhD, CIMI, CPT

Respiratory System

The most **critical** and **immediate** changes: Is the ***onset of breathing***

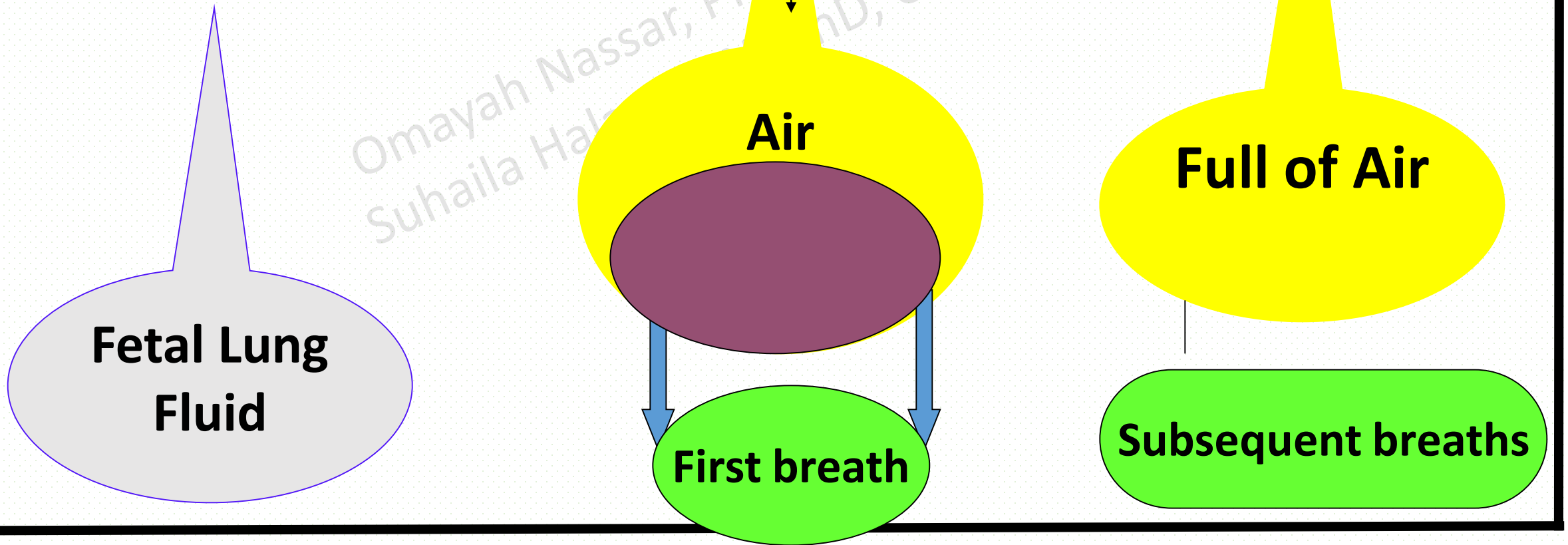

Omayah Nassar, PN, PhD, CPT
Suhaila Hal... PhD, CIMI, CPT

Initiation of breathing (changes the lung condition)

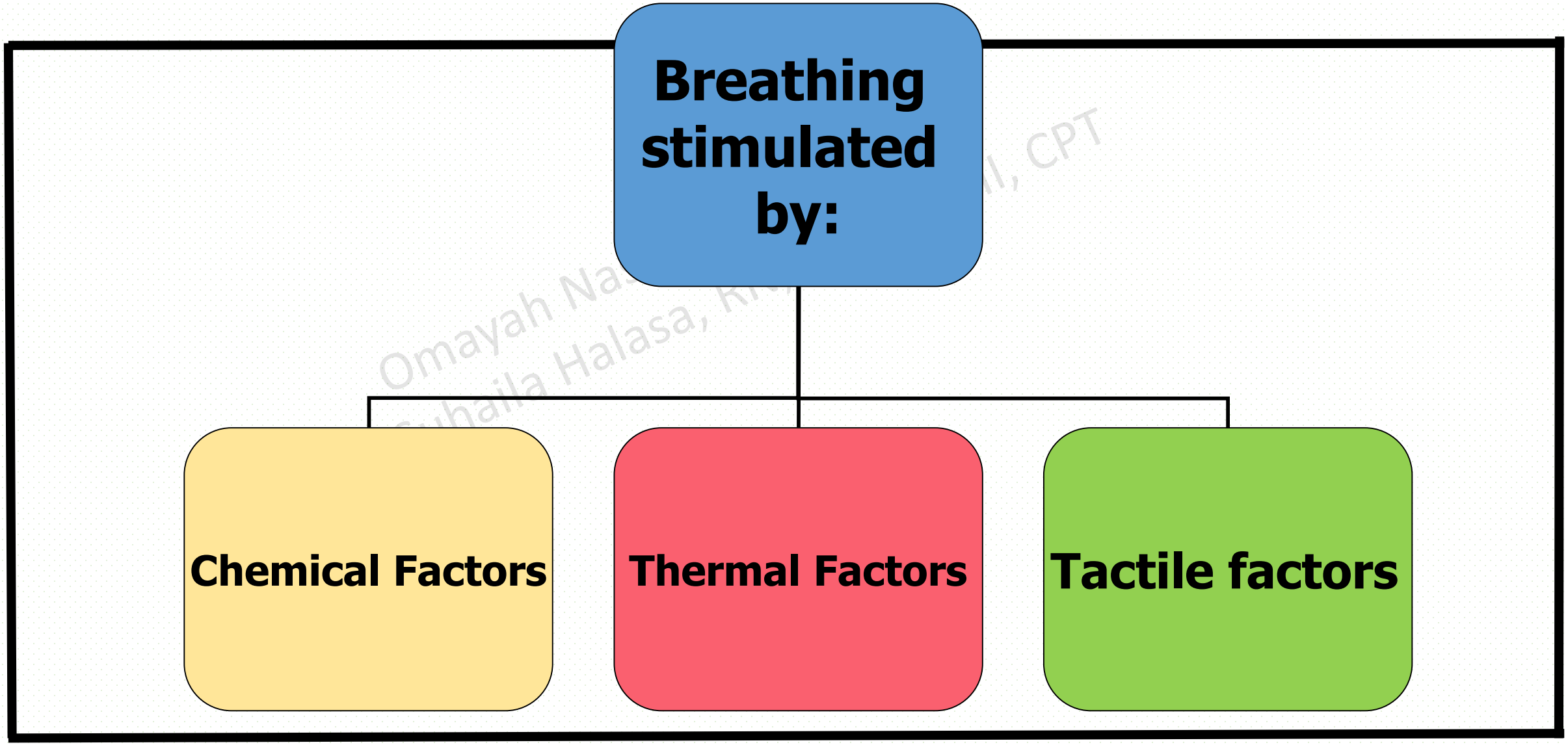

Chemical factors

Decrease Oxygen, increase Co2, low Ph

Initiation

Respiratory centre in the medulla

Omayan Alassar, RN, PhD, CPT
Suhaila Halasa, RN, PhD, CIMI, CPT

Primary Thermal Stimuli

Changes of the environment

Omayah Nassar, RN, PhD, CPT
Suhaila Halasa, RN, PhD, CIMI, CPT

The sudden chilling of the neonate

Excites sensory impulses in the skin

Transmitted to the respiratory centre

Tactile factors

- Descent through the birth canal
- Tapping the newborn's feet,
- Rubbing the torso (upper body) ,
  or Suctioning
- Slapping the newborn's buttocks
  or back is harmful and should not be done

http://momdiscuss.com/various-tips-for-newborn-skin-care/

Omayah Nassar, PN, PhD, CPT
Suhaila Halasa, RN, PhD, CIMI, CPT

Newborn Respiration

- **Fetal lung fluid removal**
  - Compression of the chest occurs with passage through the birth canal
  - Lymphatic vessels and pulmonary capillaries
- **Expansion of the alveoli**
  - Occurs with initiation of breathing
  - Role of surfactant in keeping the alveoli expanded

Omaiyah Nassar, RN, PhD, CPT
Suhaila Hamsa, RN, PHD, CIMI, CPT

The fluid is removed by

Pulmonary Capillaries

Lymphatic Vessels

Delivery & Labour

Expansion of the alveoli

During Labour & delivery

Compression on the chest

↓

Fluids is squeezed from nose &mouth

↓

Complete emergence of the neonatal chest

↓

A brisk recoil of the thorax occurs

↓

Air enters the upper air way to replace the lost fluid

Omayah Nassar, RN, PhD, CPT
Suhaila Hubasa, RN, PhD, CIMI, CPT

كلية التمريض
SCHOOL OF NURSING

Surfactant

- Remaining lung fluid is absorbed by the pulmonary capillaries and lymphatic vessels in the alveoli the surface tension of fluid is reduced by **Surfactant**

- **Surfactant:** is a substance produced by the alveolar epithelium cell that coats the alveolar surface and reduce fluid surface tension

Omayah Nassar, PN, PhD, CPT
Suhaila Halasa, RN, PhD, CHN, CPT

Surfactant

Why Preterms..????

- **TERM BABIES :**

have storage pool of approximately **100 mg/kg** of surfactant at birth.

- **PRETERM BABIES :**

have a storage pool of approx. **4-5 mg/kg** surfactant at birth.

https://www.google.jo/search?q=respiratory+distress+syndrome+in+newborn&source=lnms&tbm=isch&sa=X&ved=0ahUKEwi7nJGi253XAhVLuBoKHSTiAHEQ_AUICigB&biw=1600&bih=794#imgrc=_

What difference does it make….????

Normal Expiration With Surfactant

Abnormal Respiration Without Surfactant

https://www.google.jo/search?q=respiratory+distress+syndrome+in+newborn&source=lnms&tbm=isch&sa=X&ved=0ahUKEwi7nJGi253XAhVLuBoKHSTiAHEQ_AUICigB&biw=1600&bih=794#imgrc=_

Challenge Question

Is there a relationship between type of delivery and Respiratory Distress Syndrome (RDS)????????????

Surfactant---------- **C/S**

Omayah Nassar, PhD, CPT
Suhaila Halasa, RN, PhD, CIMI, CPT

Please Review this video

https://www.youtube.com/watch?v=rYVGjbzmAtg

The attached video presents the Fetal Circulation and newborn circulation

Omayah Nassar, RN, PhD, CPT
Suhaila Halasa, RN, PhD, CIMI, CPT

Normal Fetal Circulation

The following should be considered:

- Changes in fetal circulation (pre to post natal circulation)

- Postnatal components (some component are not required in postnatal circulation /neonatal circulation

Omayah Nasser PN, PhD, CPT
Suhaila Halasa, RN, PhD, CIMI, CPT

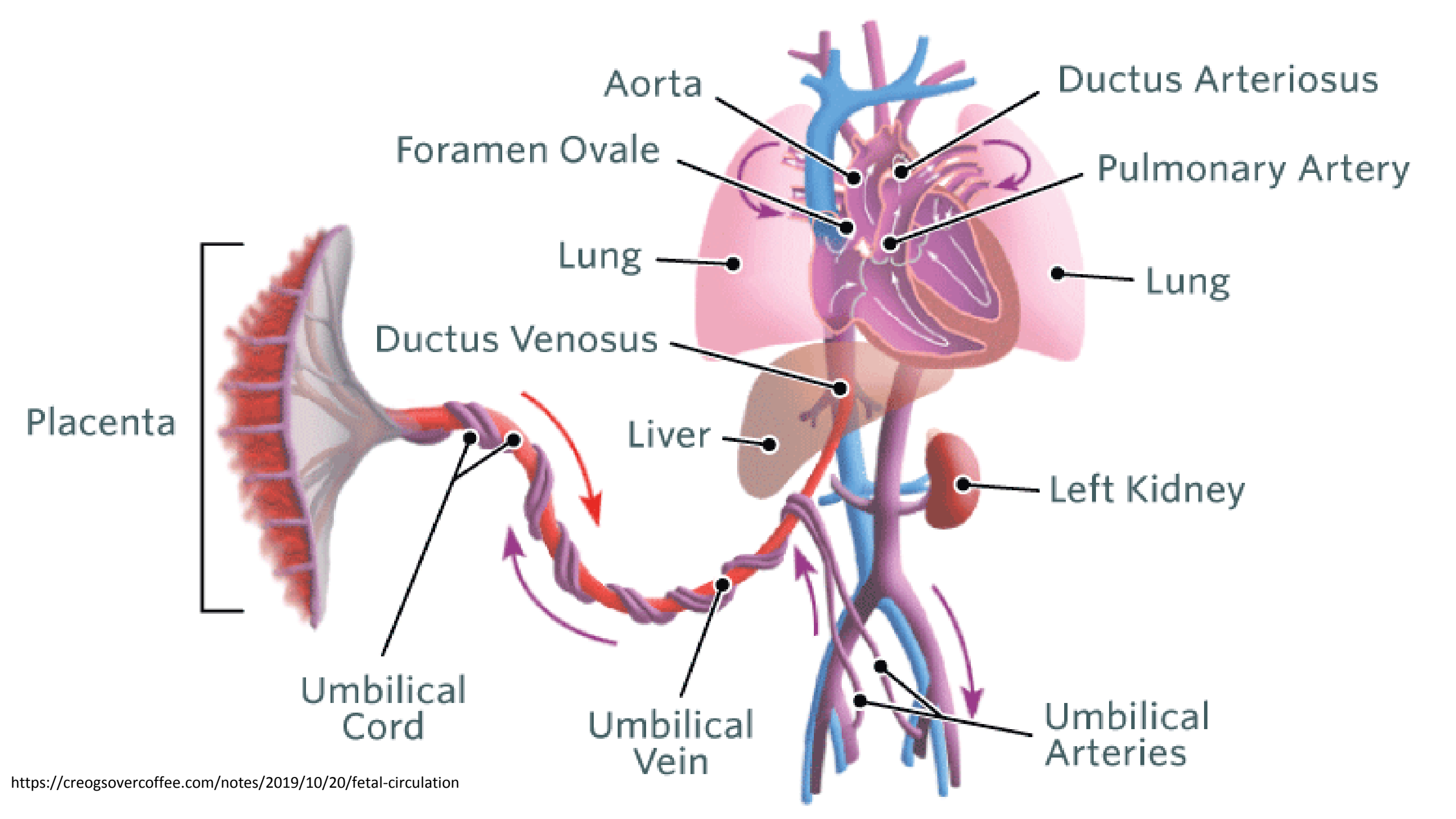

https://creogsovercoffee.com/notes/2019/10/20/fetal-circulation

كلية التمريض
SCHOOL OF NURSING

Fetal Circulation

- During fetal life, blood carrying oxygen and nutritive material from the placenta enters fetal system through the umbilical veins
- Oxygenated blood enters the heart by way of the inferior vena cava

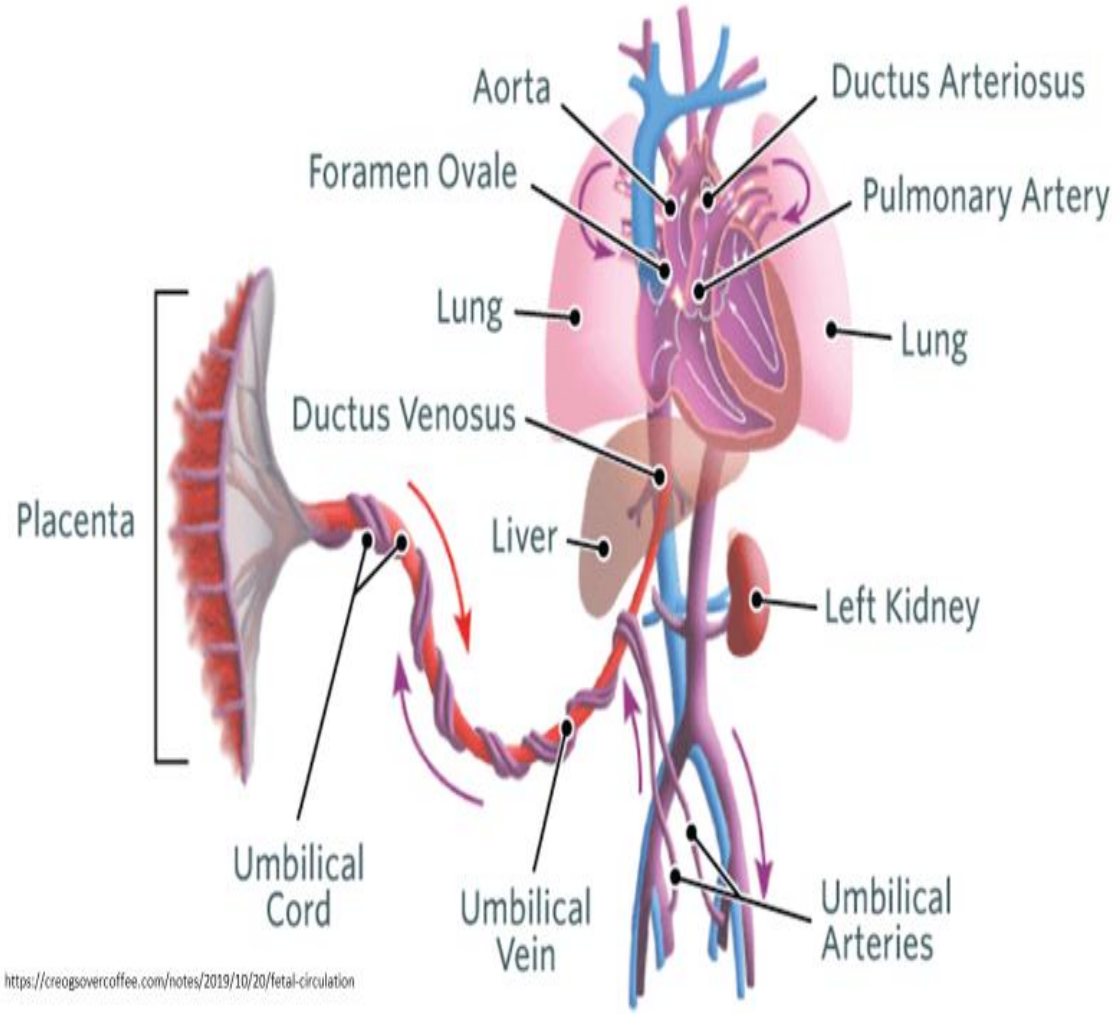

Omayah Nassar, RN, Suhaila Halasa, RN,

Fetal Circulation

- Because of the higher pressure of blood entering the right atrium, it is directed posteriorly in a straight pathway across the right atrium and through the foramen ovale to the left atrium

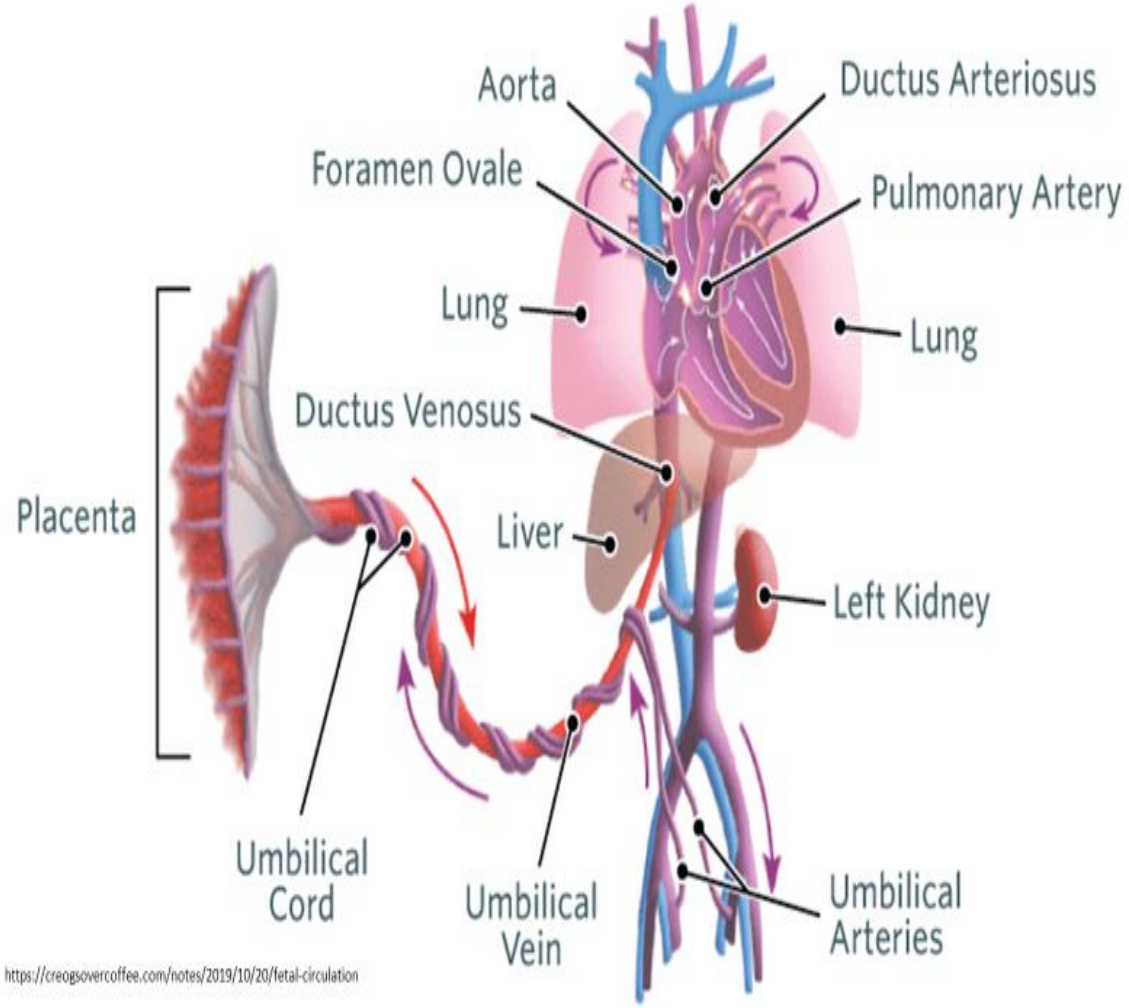

Omayah Nassar, PN, Suhaila Halasa, PN,

Fetal Circulation

- In this way the better –oxygenated blood enters the left atrium and ventricle to be pumped through the aorta to head and upper extremities

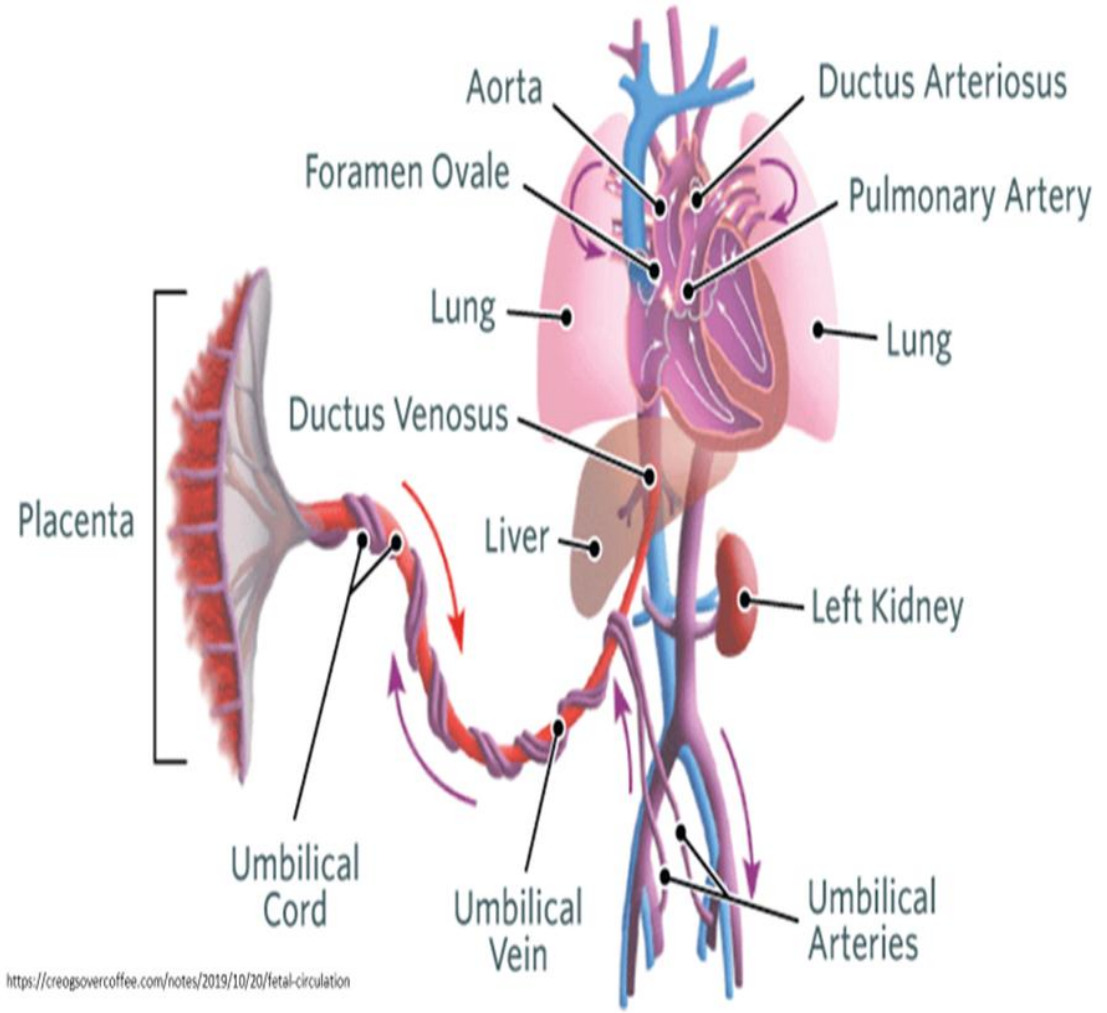

Omayah Nassar, PN, P
Suhaila Halasa, RN, P

Fetal Circulation

- Blood from the head and upper extremities entering the right atrium from superior vena cava is directed downward through the tricuspid valve into the right ventricle

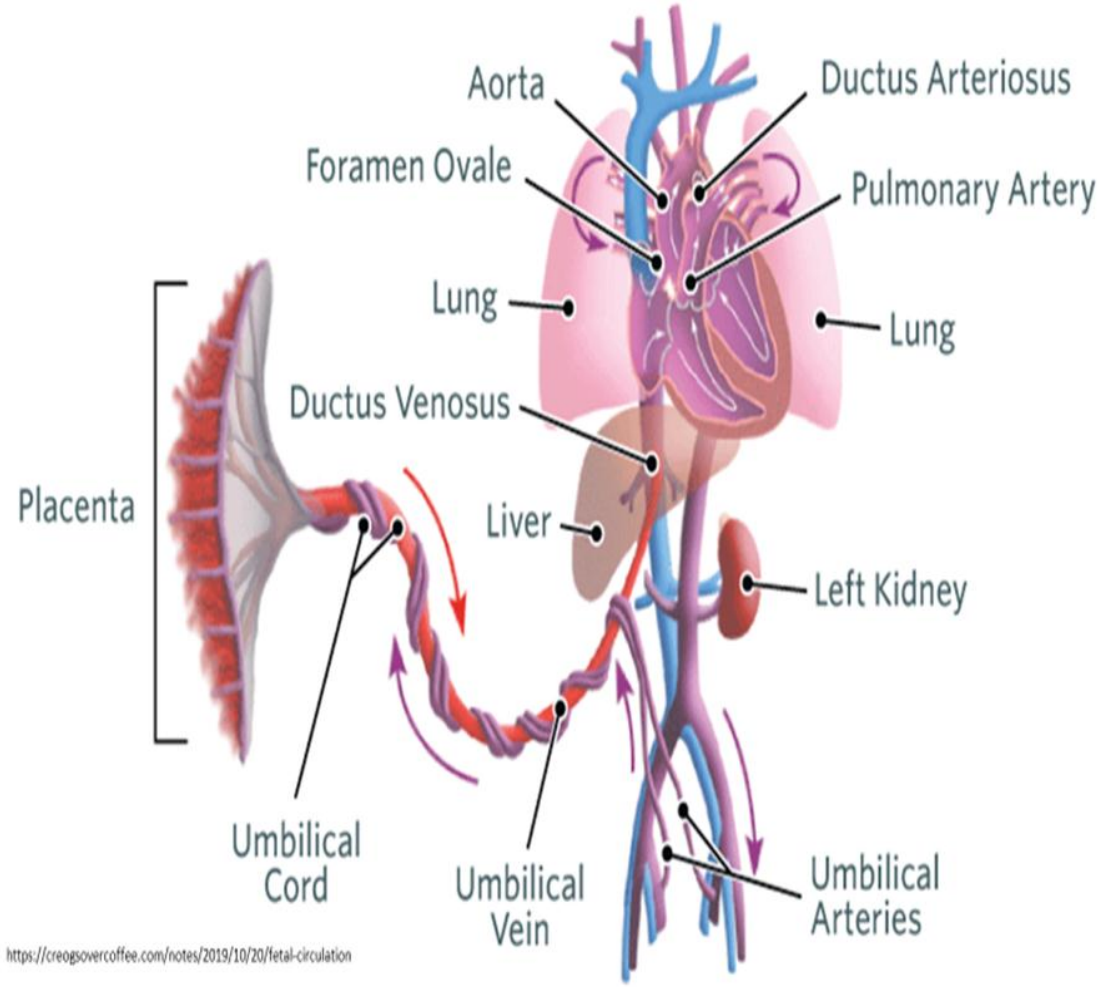

Fetal Circulation

- From here, it is pumped through the pulmonary artery, where the major portion is shunted to the descending aorta via the ductus arteriosus
- Only small amount of blood flows to and from nonfunctioning fetal lung

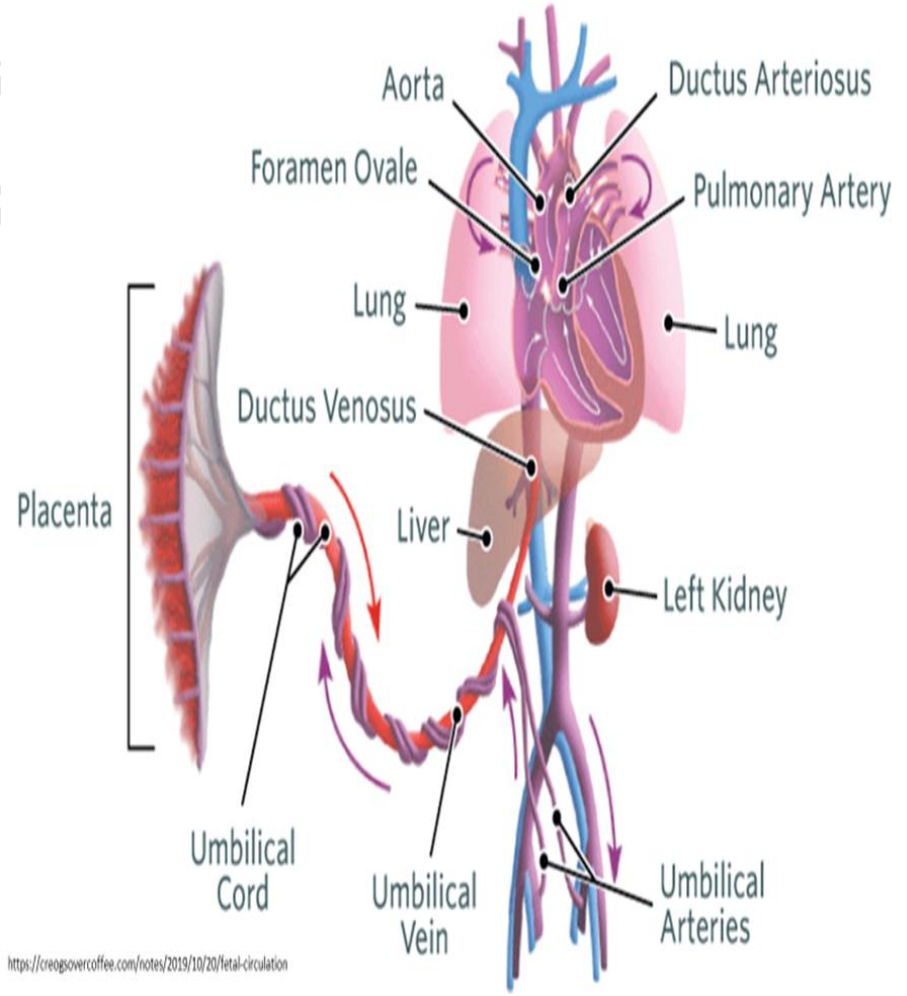

Omayan Nassar, PN, PhD, CP
Suhaila Halasa, PN, PhD, CI

Circulatory changes at birth

- With the cessation of placental blood flow from clamping of the umbilical cord and the expansion of lung at birth, the hemodynamics of fetal vascular system undergo pronounced and abrupt changes

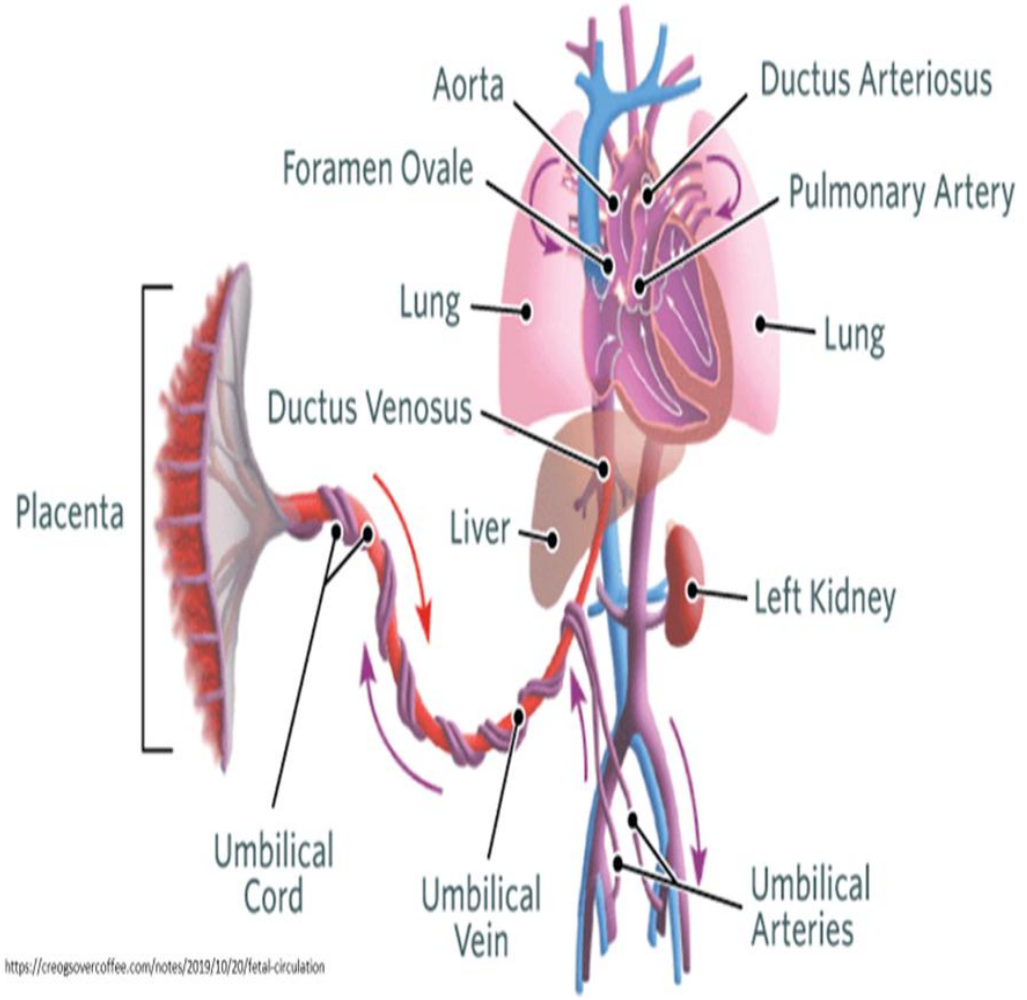

كلية التمريض
SCHOOL OF NURSING

Circulatory changes at birth

As soon as the fetus is born (Newborn) two important things happens:

- Disconnected from placenta (no placental circulation)
- Newborn will start breathing independently

Omayah Nassar, RN, PhD, CPT
Suhaila Halasa, RN, PhD, CIMI, CPT

كلية التمريض
SCHOOL OF NURSING

Circulatory changes at birth

- With the first breath, the lungs are expanded, the increased oxygen causes pulmonary vasodilation
- Pulmonary start to fall as systemic pressure, given the removal of the placenta start to rise Normally, the foramen ovale closes as the pressure in the left atrium exceeds the pressure in the right atrium

Omayah Nassar, PN, PhD, CPT
Suhaila Halasa, RN, PhD, CIMI, CPT

Altered Hemodynamic

- Normally the pressure on the right side of the heart is lower than that on the left side, Therefore, if an abnormal connection exist between the heart chambers such as septal defect, blood will necessarily from an area of higher pressure (left side) to one of lower pressure (right side)

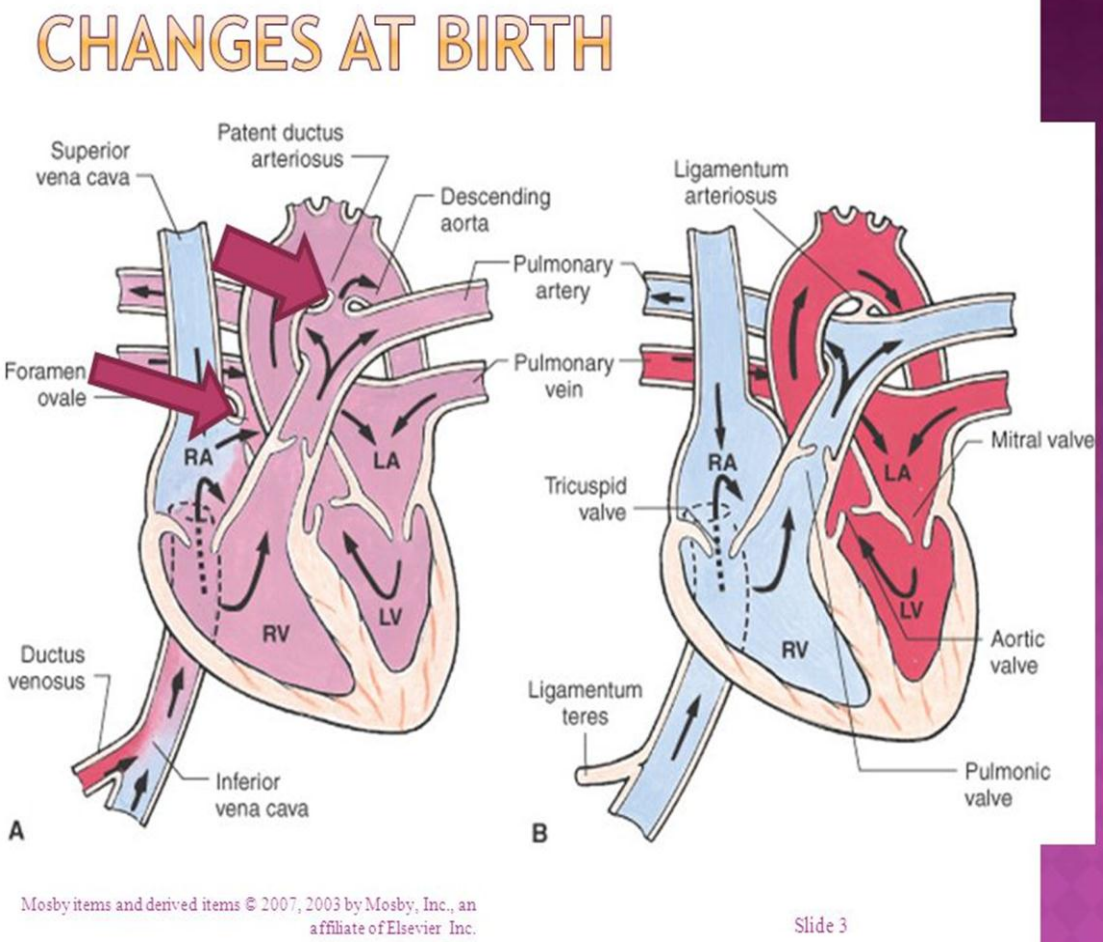

كلية التمريض
SCHOOL OF NURSING

Altered Hemodynamic

Such a flow of blood is termed a left-to-right shunt Ductus arteriosus starts to close in the presence of increased oxygen concentration in the blood and other factors

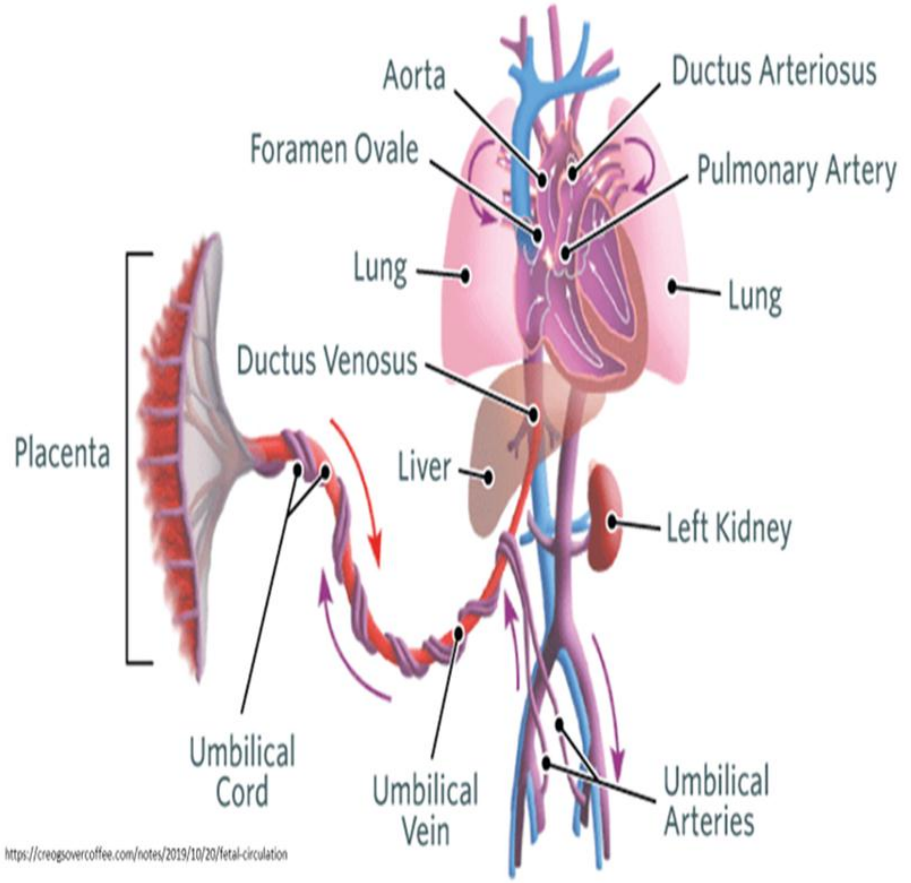

Omayah Nassar, PN, PhD, C
Suhaila Halasa, RN, PhD, C

Circulatory System

The most important factors controlling ductal closure are:

- Increase O2 concentration in the blood
- The fall in endogenous prostaglandin
- The foramen ovale closes functionally at or soon after birth
- The ductus arteriosus is closed functionally by the fourth day

Omeyyah Nassar, MN, PhD, CPT
Suhaila Hamsa, RN, PhD, CIMI, CPT

كلية التمريض
SCHOOL OF NURSING

Circulatory System

- Because of the reversible flow of blood through the ductus during the early neonatal period, a functional murmur occasionally may be heard
- In conditions such as crying or straining, the increased pressure shunts oxygenated blood from the right side of the heart across ductal opening, causing transient cyanosis

Omayah Nasser, RN, PhD, CPT
Suhaila Halasa, RN, MD, CIMI, CPT

كلية التمريض
SCHOOL OF NURSING

Circulatory System

- The changes occur as a result of pressure changes in the lungs, heart, and major vessels
- Transition from fetal circulation postnatal circulation involves the functional closure of the fetal shunts:

Omayah Nassar, PN, PhD, CPT
Suhaila Halasa, RN, PhD, CIMI, CPT

Functional Closure of Fetal Shunts

- **Ductus venosus:** Duct in the liver, connecting umbilicus venous blood with the inferior vena cava blood
- **Foramen ovale:** Opening between Right and Left atrium, functional closure soon after birth as the left atrial pressure increases

Omayah Nassar, PN, PhD, CPT
Sumaila Halasa, RN, PhD, CIMI, CHT

Functional Closure of Fetal Shunts

- **Ductus arteriosus:** Contacting two arterial system Pulmonary with Aorta, Functional closure is gradual for about 4 days after birth (as pulmonary vascular resistance decreases and O_2 increases)

Omayah Nassar, PN, PhD, CPT
Sumaila Halasa, RN, PhD, CIMI, CPT

The Fetal Shunt

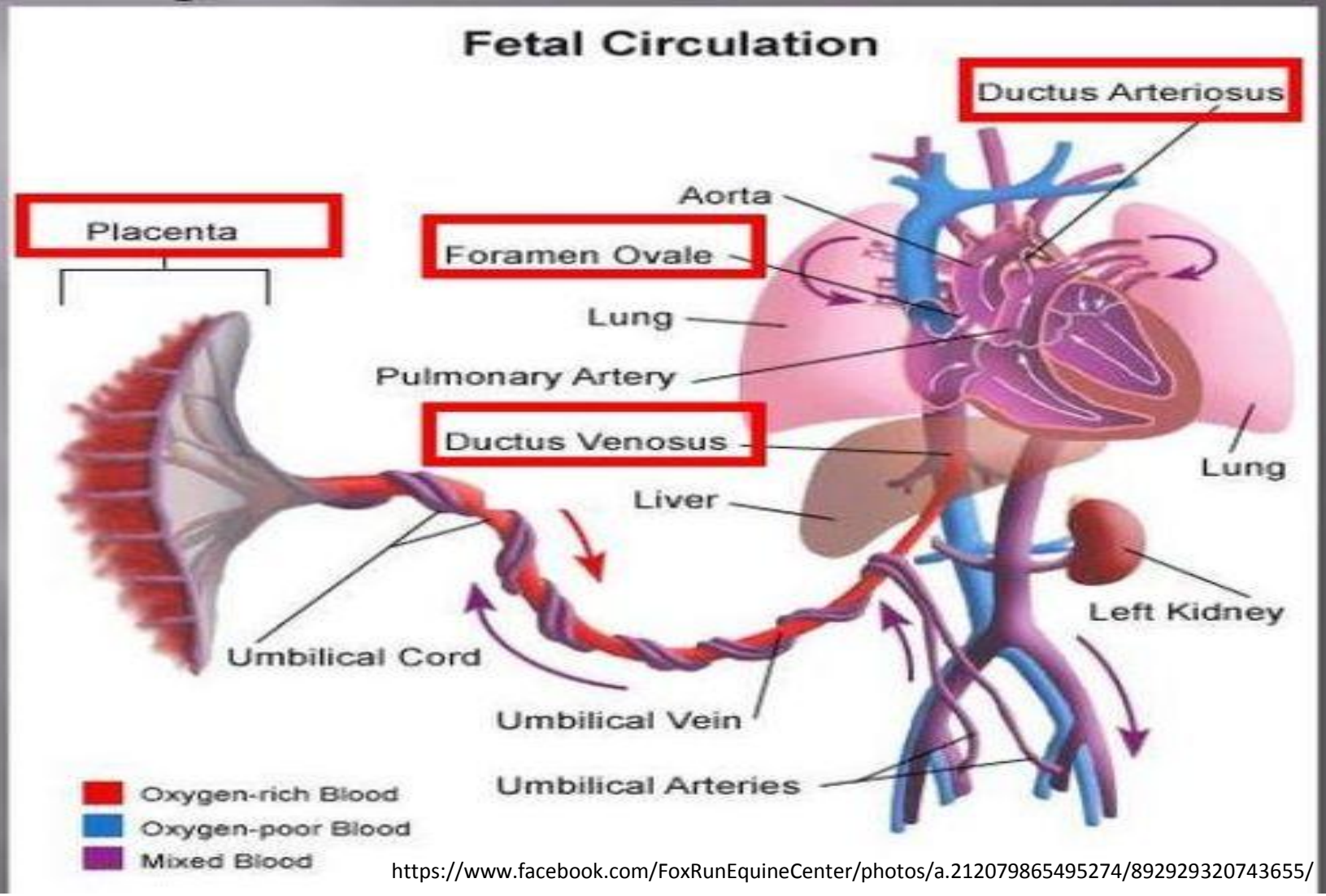

https://www.facebook.com/FoxRunEquineCenter/photos/a.212079865495274/892929320743655/

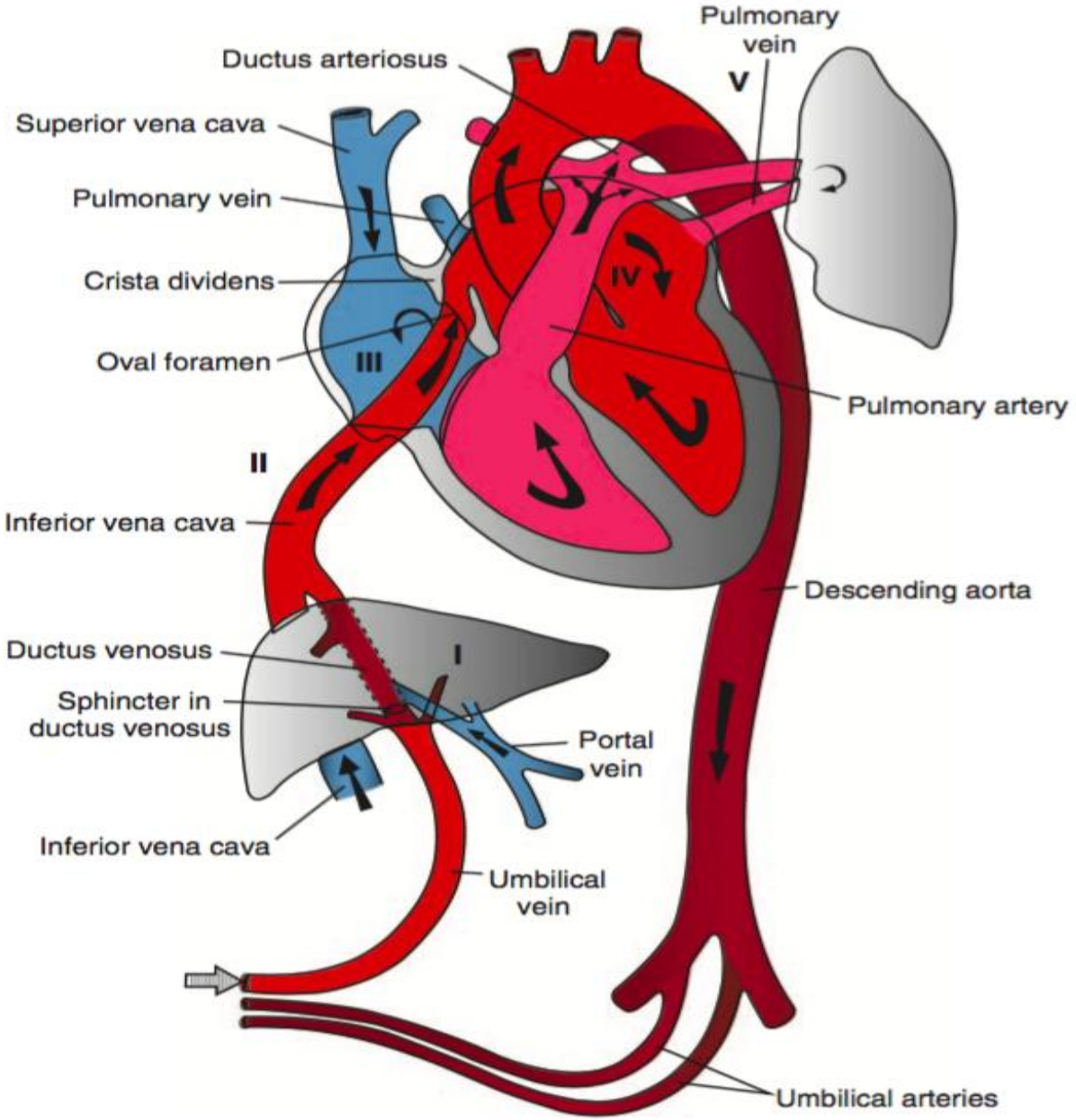

Fetal Circulation

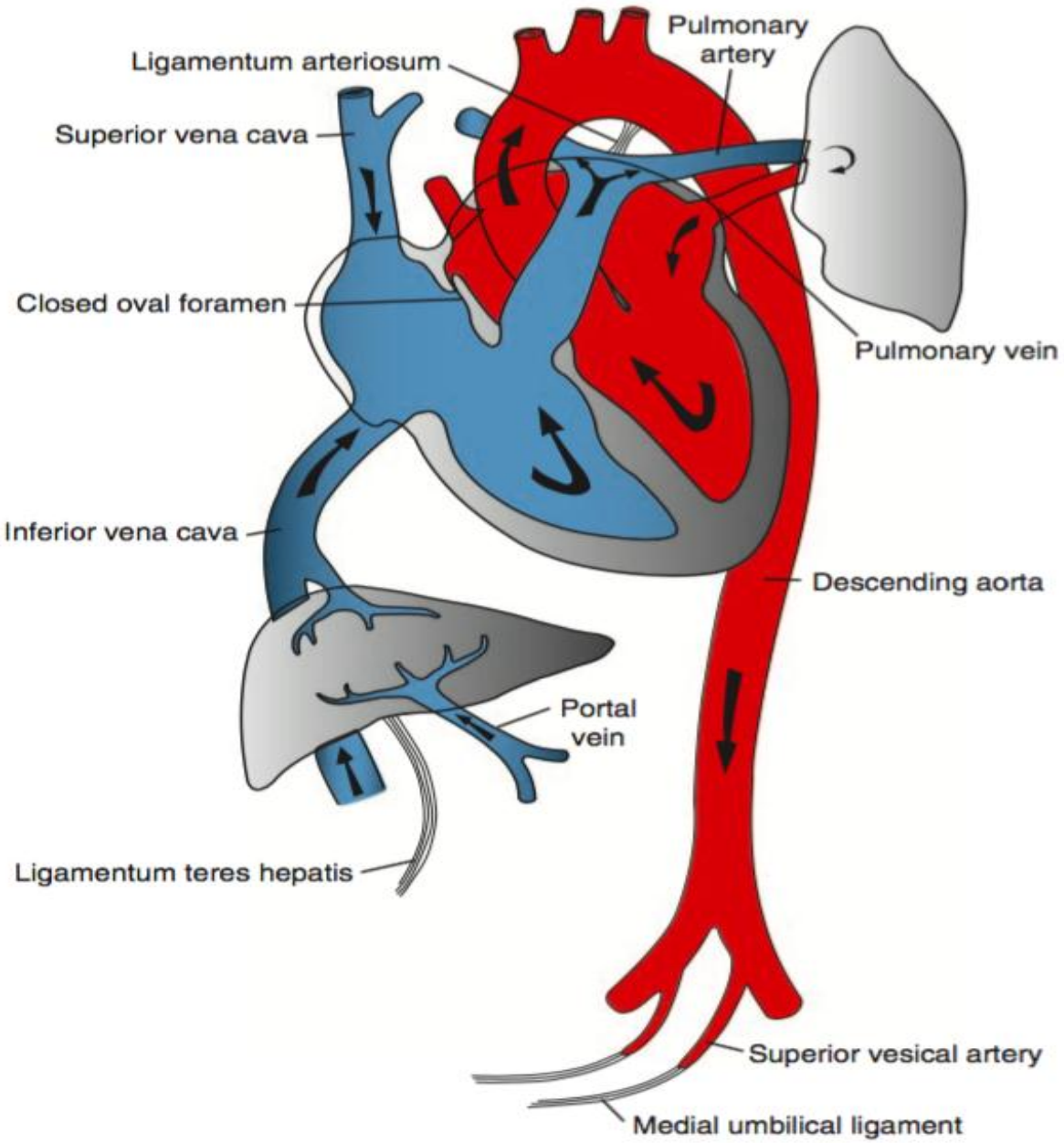

Post Transition Circulation

https://img.grepmed.com/uploads/4878/peds-circulation-anatomy-fetal-cardiology-original.png

كلية التمريض
SCHOOL OF NURSING

Are you ready for the Quiz?????

Umbilical vein
Placenta
Right atrium
Umbilical arteries
Ductus arteriosius
Superior vena cava
Foramen ovale
Inferior vena cava
Left artrium
Descending aorta
Pulmonary trunk
Pulmonary veins
Aorta
Ductus venosus

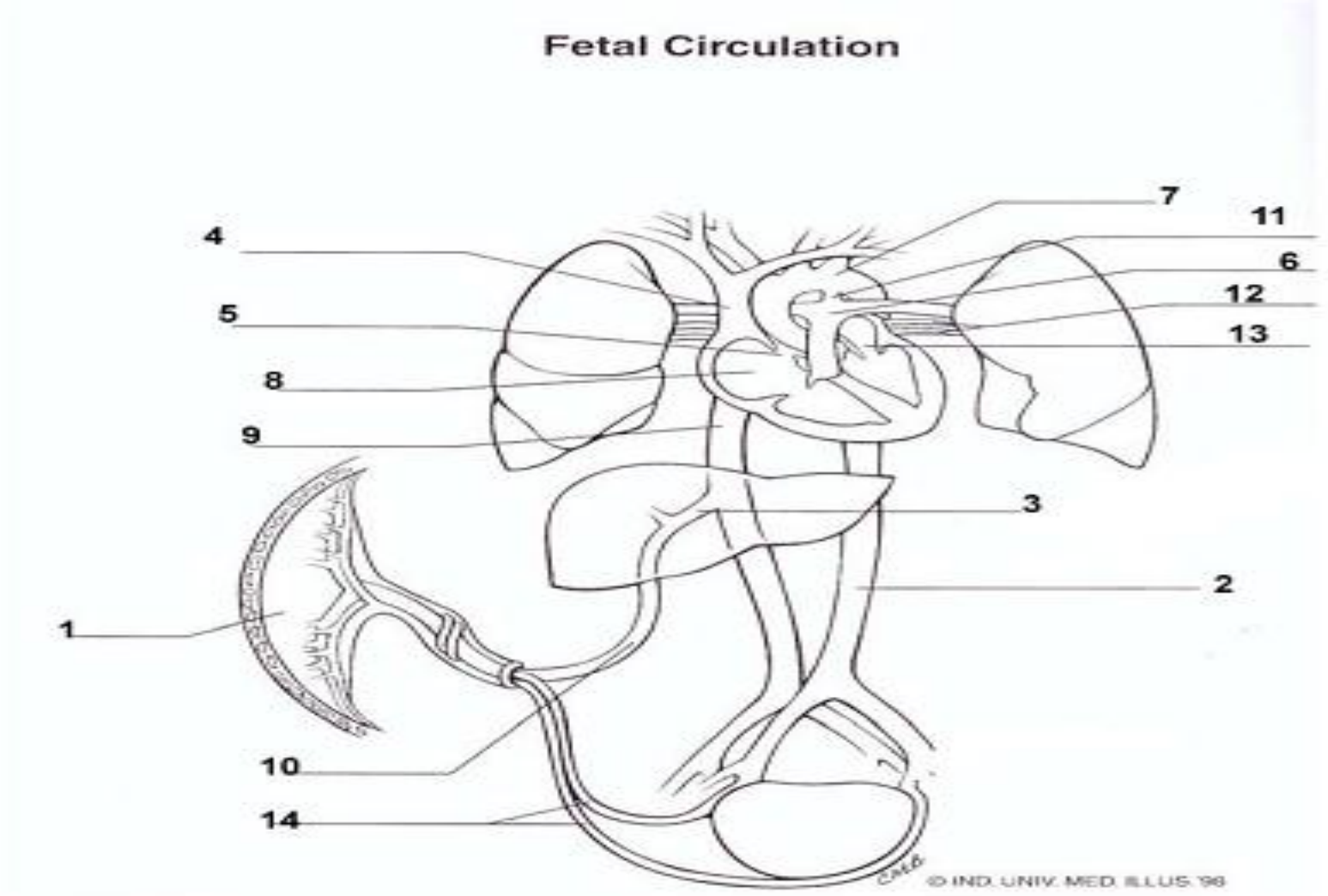

Thermoregulation

- **Critical to the newborn's survival**

- **Principal thermogenic sources:**
  - Heart
  - Liver
  - Brain
  - Brown adipose tissues (BATs)

Omayah Nasser, PN, PhD, C
Suhaila Halasa, RN, PhD, C



https://pixabay.com/en/baby-sleeping-sleeping-baby-dreaming-2073290/

Question????

- Why the nap of the neck often is warmer than the rest of the infant's body

Omayan Alassaf, RN, PhD, CPT
Suhaila Halasa, RN, PhD, CIMI, C

Thermoregulation

Brown fat: is content from mitochondrial cytochromes which has a greater capacity for heat production through intensifies metabolic activity than does ordinary adipose tissue

Omayah Nassar, RN, PhD, CPT
Suhaila Halasa, RN, PhD, CIMI, CPT

- **It consists of:**

  - Deeper layer

  - Superficial Layer

Thermoregulation

- **Deeper layers** surround the kidney, trachea, esophagus, adrenal and some major arteries

- **Superficial deposits of brown fat are located:**
  - between scapulae,
  - around the neck,
  - axilla, and
  - behind the sternum

https://s3.studentvip.com.au/notes/11100-sample.pdf

Nonshivering thermogenesis
The distribution of brown adipose tissue (brown fat)

كلية التمريض
SCHOOL OF NURSING

Thermoregulation

Ways to serve newborn temperatures:

Omayah Alassar, PN, PhD, CPT
Sumaila Halasa, PN, PhD, CIMI, CPT

- Placed skin- to- skin with their mothers after delivery
- Quickly drying of the newborn after delivery: warm, dry blankets and place newborn under radiant warmer

Factors Predisposing the Newborn to Excessive Heat Loss

- **Large body surface** area results in loss of heat to the environment
- **Thin layer** of adipose tissue is a poor insulator
- **Cannot shiver** to increase heat production
- Newborn's **mechanism for producing heat** is different from adult, so they produce heat by non shivering thermogenesis: brown adipose tissue and brown fat

Omayah Nasser PN, PhD, CPT
Suhaila Halasa, RN, PhD, CIMI, CPT

Hematopoietic System

- Blood volume depends on placental transport of blood
- In a full-term newborn, the blood volume is approximately

  80 to 85 mL/kg body weight

- Average blood volume for a newborn is **500 mL ± 100 mL**

Omayah Nassar, PN, PhD, CPT
Sumaya Halasa, RN, PhD, CIMI, CPT

Fluid and Electrolytes

- Newborn body weight is **73%** fluid (in an adult, it is 58% fluid)
- Infant has a higher ratio of extracellular fluid than an adult
- Higher level sodium & chloride, & lower level of K & Mg,& P.
- Infant has a higher level of metabolism in relation to body weight than an adult

Omayah Nassar, PN, PhD, CPT
Suhaila Halasa, RN, PhD, CIMI, CPT

Fluid and Electrolytes

Factors that make the infant more prone to problems of dehydration , acidosis or/and over hydration:

- Fluid exchange being seven times greater in infant than adult.
- The infant's rate of metabolism is twice as great in relation to body weight
- Kidneys immature so cannot concentrate urine to conserve body water increase acidity.

Omayah Nassar PN, PhD, CPT
Suhaila Halasa, RN, PhD, CIMI, CDT

Gastrointestinal System

- Newborn has a deficiency of pancreatic lipase for fat absorption, which makes cow's milk indigestible

  (lipase & amylase)

- Stomach capacity is small (5 to 60 mL), with lower esophageal pressure and delayed emptying

- Salivary glands do not secrete saliva until about 2 to 3 months of age

Omayah Nassar, PN, PhD, CPT
Sumaila Halasa, RN, PhD, CIMI, CPT

Gastrointestinal System

- Colon has small volume; the intestine is longer in relation to body size, with rapid peristaltic waves
- Infant's intestine is longer in relation to body size than adult __ large number of secretary gland and large surface for absorption __ rapid peristaltic waves.

Omayah Nassar, PN, PhD, CPT
Sumaila Halasa, RN, PhD, CIMI, CPT

Gastrointestinal System

- Drooling begins at 2 to 3 months

Spleen:

- Enzymes are adequate to handle the protein and simple carbohydrates

  (monosaccharide and disaccharides)

Omayah Nassar, PN, PhD, CPT
Suhaila Halasa, RN, PhD, CIMI, CPT

Gastrointestinal System

Liver: (90-140 gram), is the most immature of GE organs

- Every normal newborn will experience the following:

Omayah Alassar, PN, PhD, CBT
Sumaila Halasa, RN, PhD, CIMI, CBT

- Decrease glucuronyl transferase → jaundice

- Decrease plasma protein concentration → edema at birth

- Less store glycogen → hypoglycemia

  which may be prevented by early and effective feeding, especially breast- feeding

Gastrointestinal System

- Low Prothrombin and other coagulation factors → bleeding

Therefore, Vitamin K IM (0.5-1 gram) should be given within the first 72 hours

- Action and site of Injection
- Side effect of Vitamin K

Omayah Nasser, PN, PhD, CPT
Suhaila Halasa, RN, PhD, CIMI, CPT

Gastrointestinal System

Regurgitation is common because of:

1. **Rapid peristaltic waves** (Migrating Motor Complex, MMC)

2. **Immaturity of MMC** combined with decreased lower esophageal sphincter (LES) pressure

3. **Inappropriate relaxation** of the LES

4. **Delayed gastric emptying**

Omayah Nassar, RN, PhD, CPT
Sawalha Halasa, RN, PhD, CIMI, CPT

Any normal Newborn experiences------

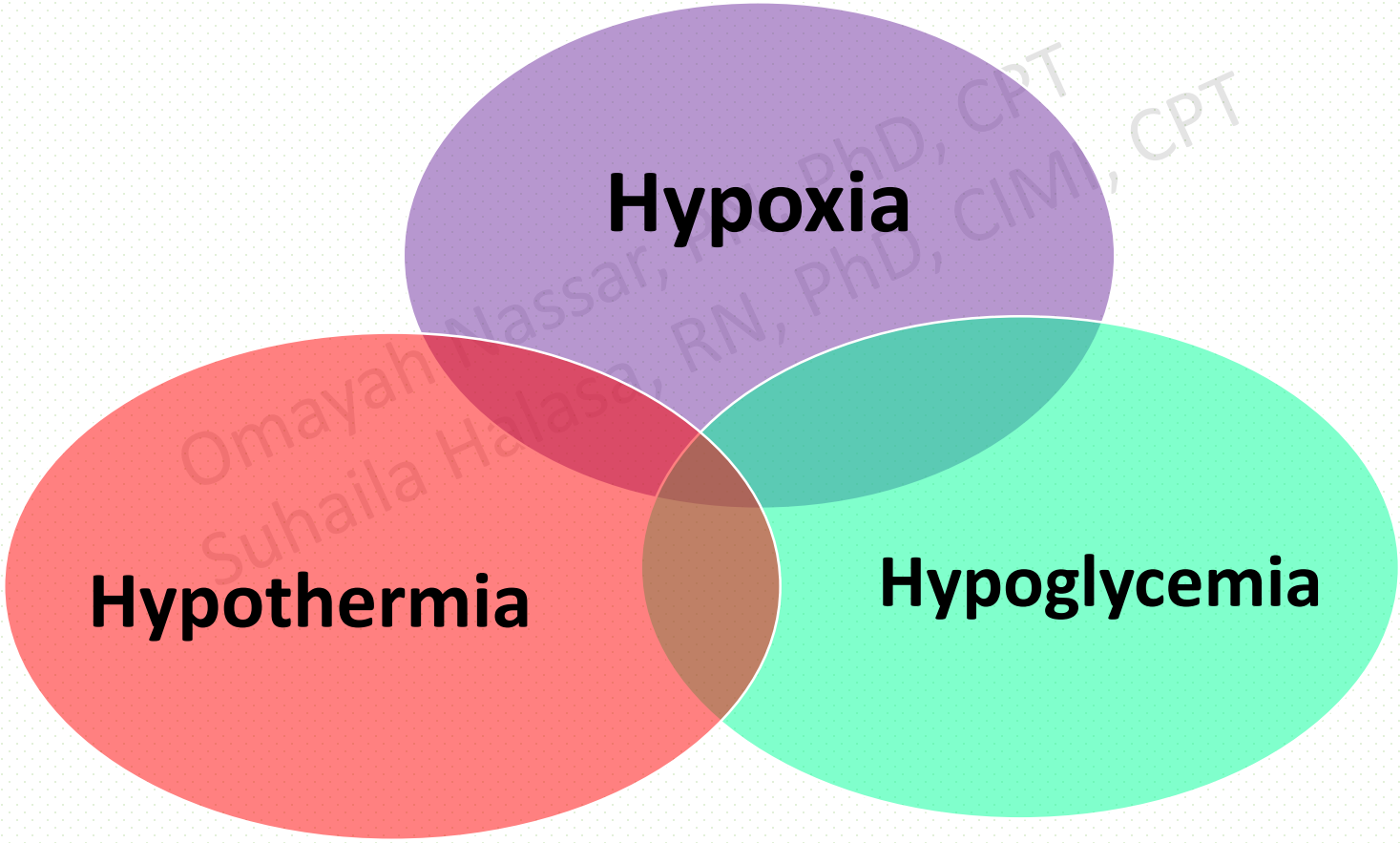

Omayah Nassar, RN, PhD, CPT
Suhaila Halasa, RN, PhD, CIMI, CPT

كلية التمريض
SCHOOL OF NURSING

Gastrointestinal System

Change in stooling Patterns of Normal Newborn

Omayah Nassar, PN, PhD, CPT
Suhaila Halasa, RN, PhD, CIMI, CPT

- Meconium
- Transitional Stool
- Milk Stool (Breast feeding and Formula milk)

Gastrointestinal System

Change in stooling Patterns of Normal Newborn

Omayah Nassar, PN, PhD, CPT
Suhaila Hamdan, RN, PhD, CIMI, CPT

Meconium

- **First stool**; composed of amniotic fluid and its constituents, intestinal secretions, shed mucosal cells, and possibly blood

(ingest maternal blood or minor bleeding of alimentary tract vessels)

كلية التمريض
SCHOOL OF NURSING

Gastrointestinal System

When does the newborn CAN pass meconium normally ?

Majority from **6-8** hours after birth

Maximum 24 to 48 hours after birth

Intestinal obstruction (Mega colon)??

Omayah Nassar, PN, PhD, CDT
Suhaila Halasa, RN, PhD, CIMI, CPT

Gastrointestinal System

Transitional Stools

Usually appear by 3rd day after initiation of feeding; Greenish brown to yellowish, thin, and less sticky than meconium; may contain some milk curds

Suhaila Nassar, RN, PhD, CPT
Suhaila Nassar, RN, PhD, CIMI, CPT

Gastrointestinal System

Milk stool

Dr. Eyah Nassar, PN, PhD, CPT
Suhaila Hajasa, RN, PhD, CIMI, CPT

- Usually appears by the **fourth day**
- In **breast – feed** infants' stool are **yellow** to golden, are pasty in consistency, and have an odor similar to that of sour milk
- In **formula-fed** infants' stools are pale yellow to **light brown**, are firmer in consistency, and have a more offensive odor

A breastfed baby

A formula fed baby

A baby taking iron

Meconium



Diarrhea

Bloody stool

https://www.facebook.com/malishmalaysia/photos/a.627089700658269/1008203475880221/

Baby poo: What's normal for breastfed babies from day 1 and beyond

Day one

Baby will have a small amount of colostrum, (the early yellow /gold milk) each feed, at least one wet nappy and possibly sticky, black poo called meconium.

Day two

Baby will continue to get small amounts of colostrum at each feed. At least two wet nappies and less sticky black poo.

Day three

Breastmilk is increasing now. Baby will have at least three wet nappies and poo will likely become greenish-brown and be softer.

Day four

At least four wet nappies and poos becoming a lighter green-brown or may have changed to a mustard yellow and can be 'seedy' or watery.

Day five

Breastmilk supply is increasing so there will be at least six-eight heavy/wet cloth nappies or five heavy/wet disposable nappies. Poo mostly mustard -yellow soft or liquid three to four times in 24 hours.

kidspot .com.au

https://cdn.newsapi.com.au/image/v1/c57dcd9c0ada5ee8e20fae0307b3467d

Implications for Gastrointestinal System

- Human milk is the best food for a newborn
- Immature liver contributes to physiologic jaundice and edema at birth
- Increased risk for hypoglycemia
- Small, frequent feedings are required
- Frequent “stooling” (at every feeding) is common

Omayah Nassar, RN, PhD, CPT
Suhaila Al-Jasa, RN, PHD, CIMI, CPT

Renal System

- Functional deficiency in the kidney's ability to concentrate urine
- Normal newborn urine production is **1 to 2 mL/kg/hour**

- **If the birth weight for a normal newborn is 3kg, calculate the total amount of urine that should be passed per day**

- **1- 2 ml/kg → 3 - 6 ml/hour**
- **For 24 hours → 24 h x 3 ml - 24 h x 6 ml =**

  72 ml – 144 ml/ 24 hour

Omayyah Nassar, PN, MD, CPT
Suhaila Halasa, RN, PhD, CIM, CPT

Renal System

- Bladder capacity is approximately **15 to 30 mL**, resulting in emptying as many as 20 times per day
- First void should occur within 24 hours after birth
- Urine is colorless and odorless and has a specific gravity of approximately 1.020

Omayah Nassar, PN, PhD, CPT
Suhaila Halasa, RN, PhD, CNM, CPT

Endocrine System

- Limited quantities of antidiuretic hormone or vasopressin, which inhabit diuresis, therefore, infants are highly susceptible for dehydration
- **Effects of maternal hormones:**
    1. breast engorgement (both sex)
    2. pseudo menstruation & vaginal discharge (female)
    3. hyper trophy of labia (female)
    4. hydrocele (edema of the scrotum)(male)

Omayah Nassar, PHN, PhD, CPT
Suhaila Halasa, RN, PhD, CNM, CPT

Endocrine System

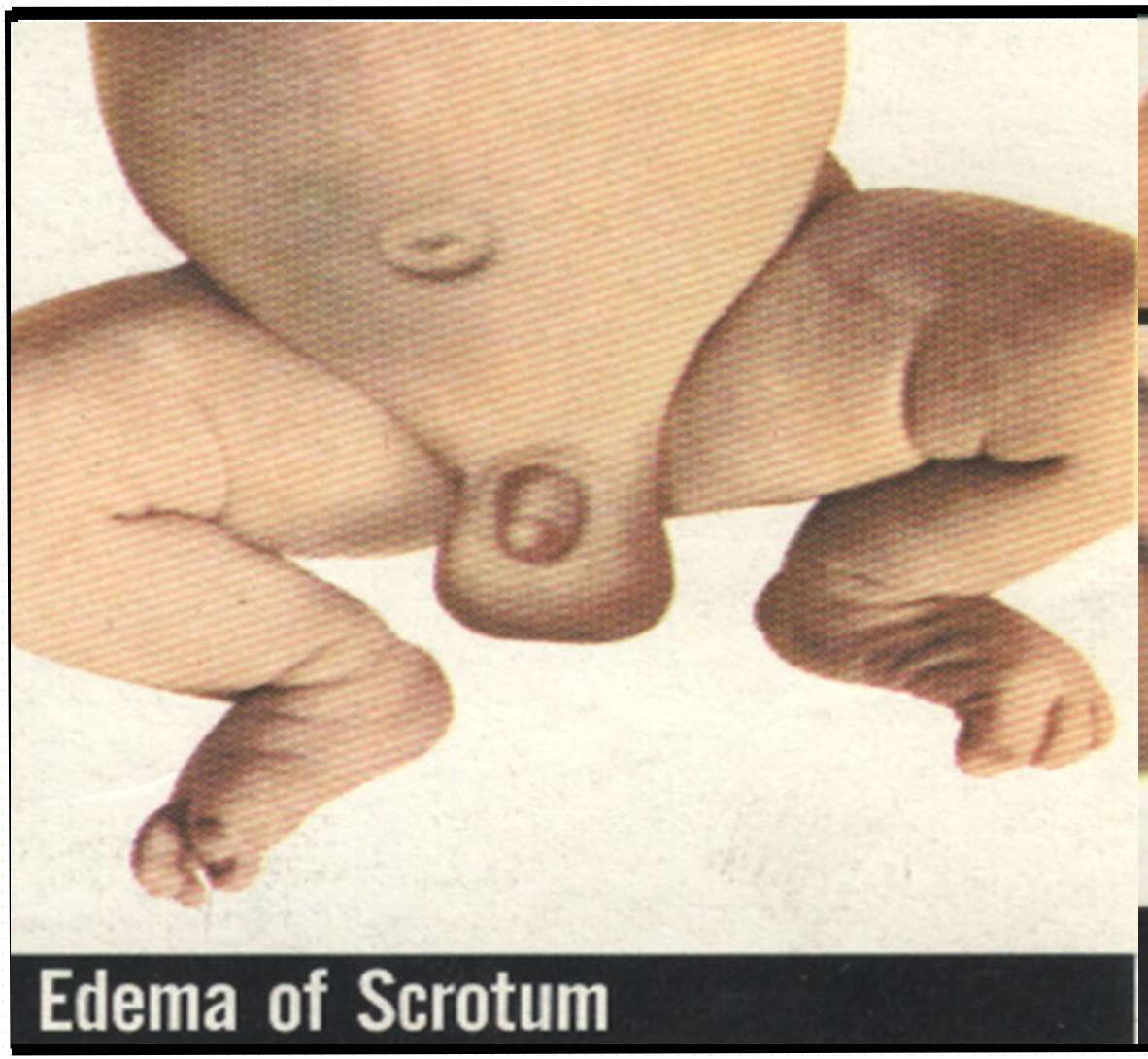

Edema of Scrotum

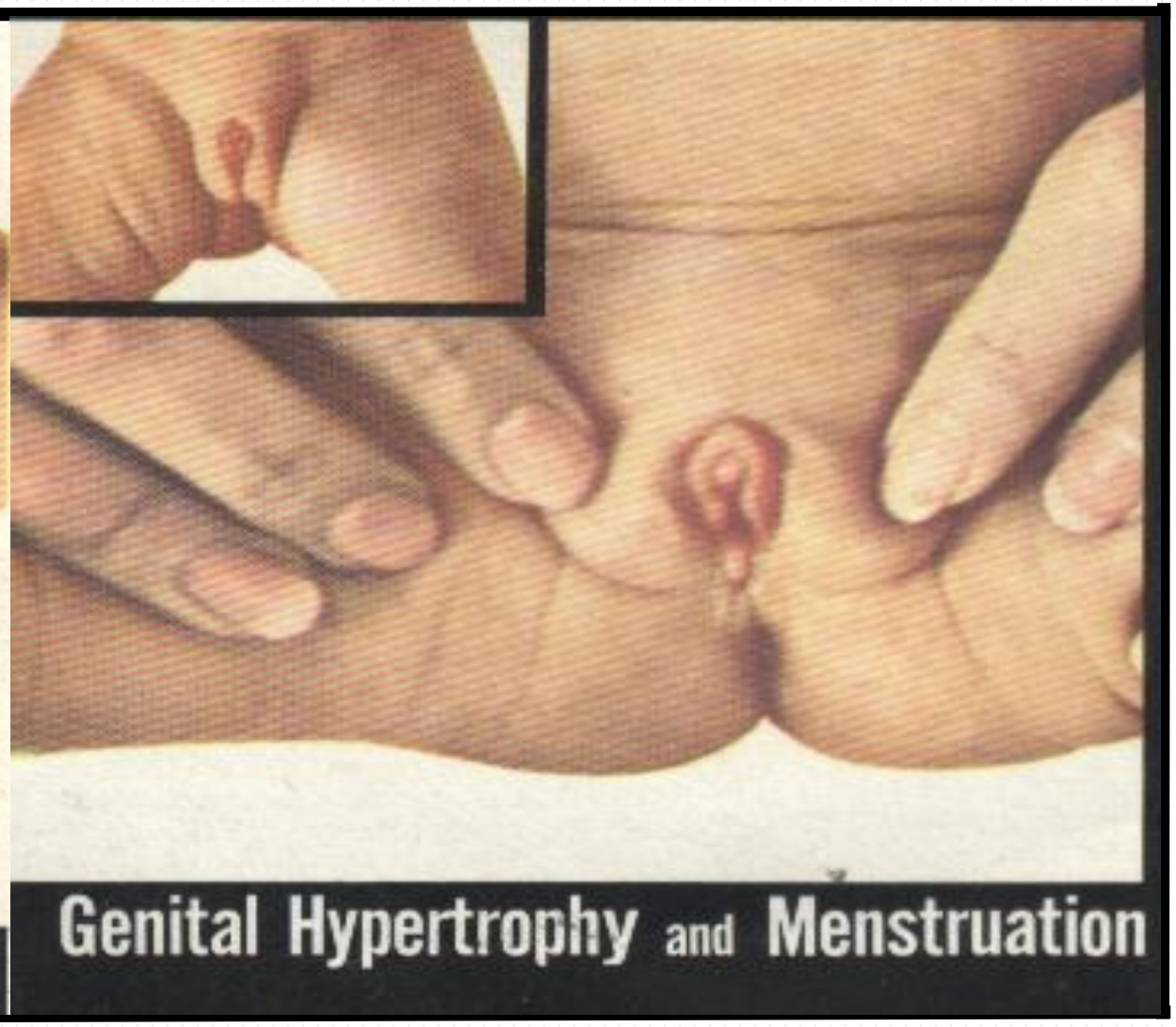

Genital Hypertrophy and Menstruation

كلية التمريض
SCHOOL OF NURSING

Breast Engorgement

- Definition
- Cause
- Clinical manifestations
- Age group
- Appearing and Disappearing time
- Treatment
- Health education to the parents

Omayah Nassar, PN, PhD, CPT
Suhaila Halasa, RN, PhD, CIMI, CPT

كلية التمريض
SCHOOL OF NURSING

Breast Engorgement

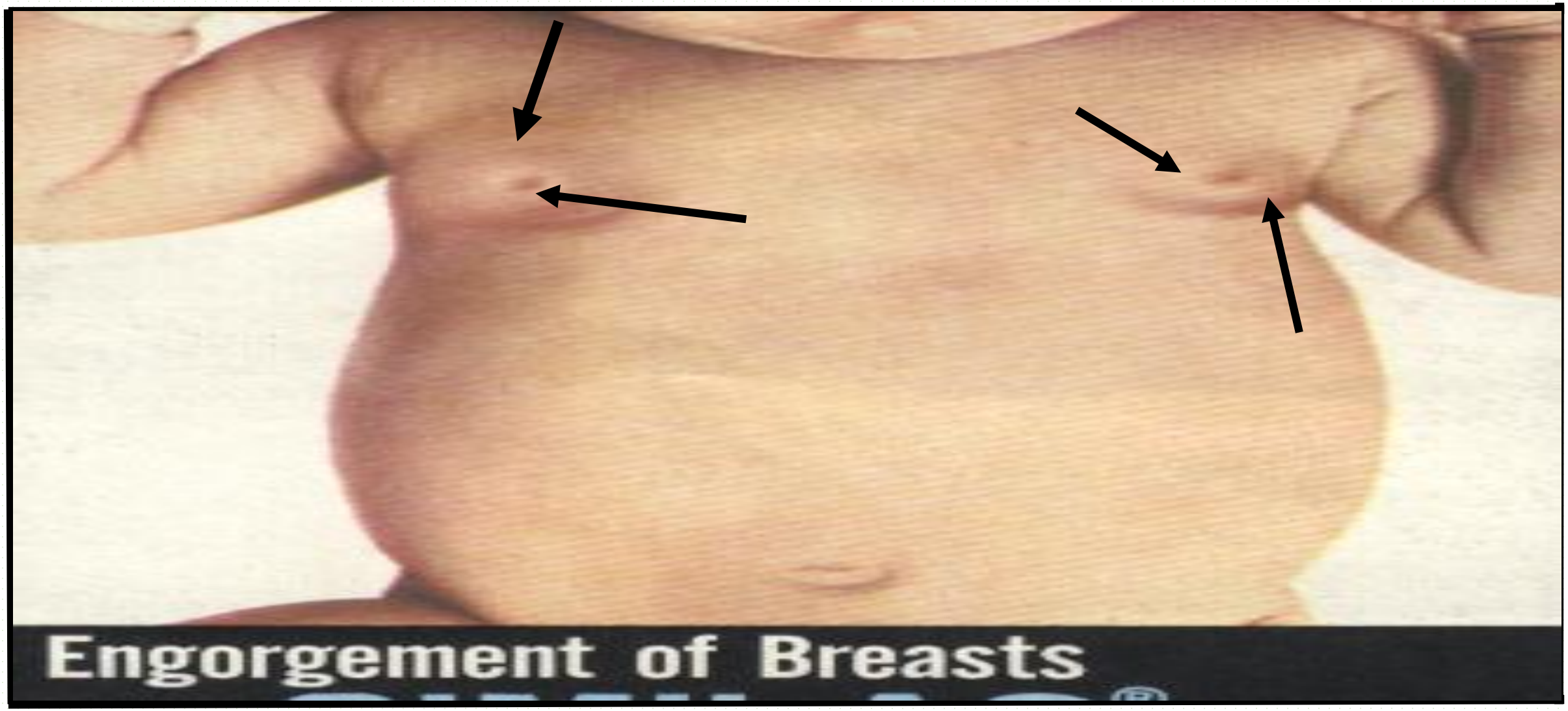

Integumentary System

- Immature function; outer layers are very thin → risk for injury
- The epidermis and dermis, are loosely bound to each other and are very thin
- Slight friction across the epidermis, such as from rapid removal of tap, that cause → separation of these layers & blister formation or loss of the epidermis

Omayan Nassar, PN, PhD, CPT
Suhaila Halasa, PN, PhD, CIMI, CPT

Integumentary System

- Active sebaceous glands
- Eccrine (sweat) glands are functional (major sweat glands)of the human body
- Apocrine glands are small and nonfunctional (secrets oily fluid with protein, lipids, and steroids, that is odorless before microbial activity
- Growth phases of hair follicles are not in synchrony with hair loss
- Amount of melanin is low at birth; skin is lighter than in later life; ultraviolet susceptibility

Omayah Nassar, PN, PhD, CPT
Suhaila Nalasa, RN, PhD, CIMI, CPT

Integumentary System

- The eccorine glands which produce sweat in response to heat or emotional stimuli are functional at birth. And palmer sweating on crying reach level equivalent to those of anxious adults by 3 weeks of age

- The apocrine glands remain small & nonfunctional until puberty

- Hair follicles: over growth of hair or temporary alopecia

Omayah Nassar PN, PhD, CPT
Suhaila Halasa, RN, PhD, CHN, CPT

Integumentary System

- Melanin is low at birth; newborn has lighter skin than they will be as a children
- The sebaceous glands are very active late in fetal life and in early infancy because of high level of maternal androgens → locate on scalp, face, and genitalia and produce the **greasy vernix caseosa** that cover the infant at birth.

Omayan Nassar, PN, PhD, CPT
Suhaila Halasa, PN, PhD, CIMI, CPT

Musculoskeletal System

- Skeletal system contains more cartilage than ossified bone
- Rapid ossification in the first year of life
- Muscular system is almost completely formed at birth
- Muscle growth is by hypertrophy rather than hyperplasia

Omayah Nassar, PN, PhD, CPT
Suhaila Halasa, RN, PhD, CIMI, CPT

كلية التمريض
SCHOOL OF NURSING

Common Variations

- Definition of common variation
- Cause
- Site (area)
- When it appears and disappears
- Any associated factors

Ghayah Nassar, PN, PhD, CPT
Suhaila Halasa, RN, PhD, CIMI, CPT

كلية التمريض
SCHOOL OF NURSING

Common Variations

https://www.google.as/search?q=newborn+adjustment+to+extrauterine+life&

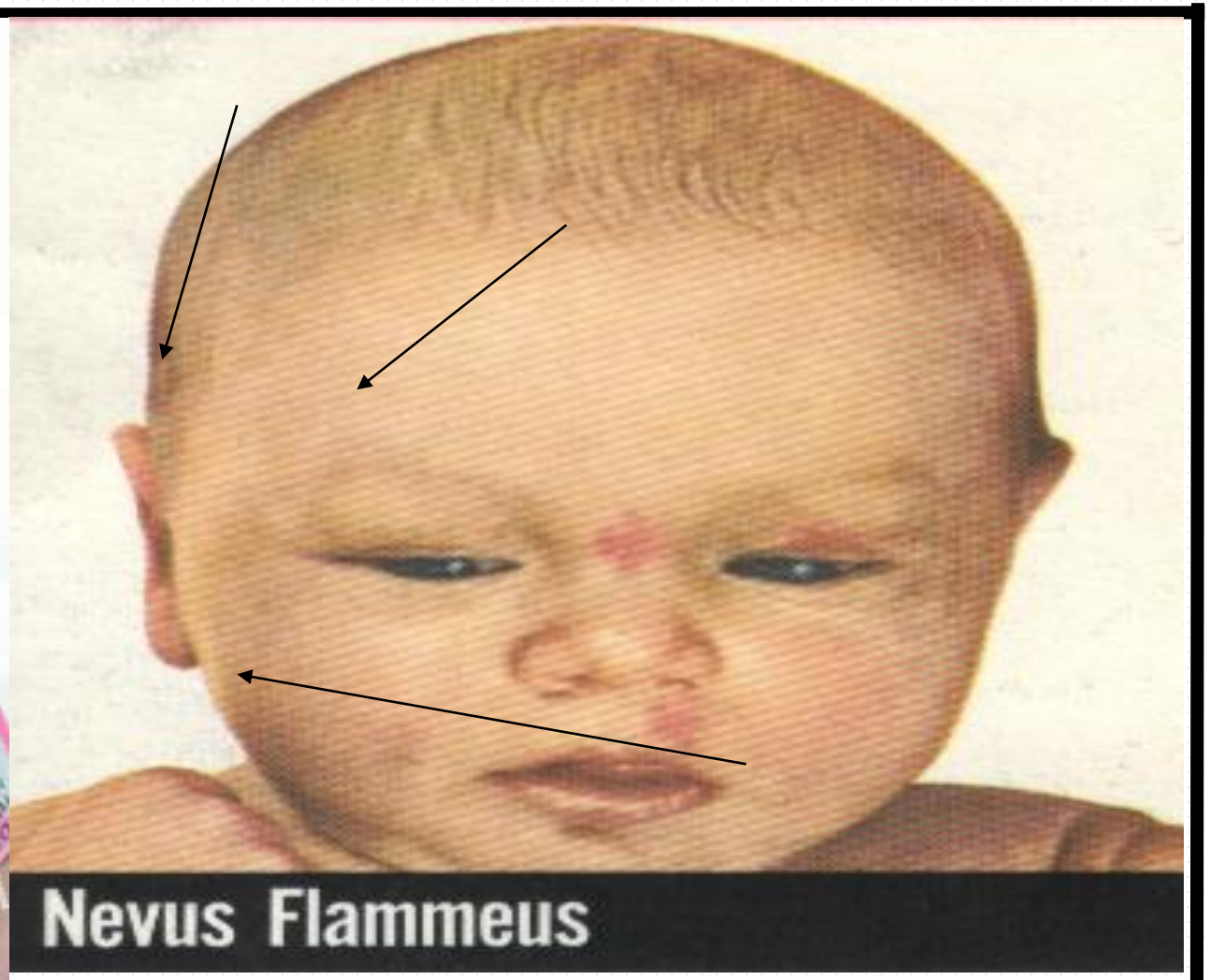

كلية التمريض
SCHOOL OF NURSING

Common Variations

https://www.google.jo/search?q=common+variations+in+the+newborn&tbm=isch&tbs=rimg:CUWD9g2FGOGBIji8Uqv52xAPdFROKiczsE1nKy2_19M-fV3qnUB4Q_1-QwcmukR4Z3yV9s1ePYtqS-PuS93gFVOKS8GioSCbxSq_1nbEA90EQl7JrOMFyA8KhIJVE4qJzOwTWcRCXsms4wXIDwqEgkrLb_

كلية التمريض
SCHOOL OF NURSING

Common Variations

http://www.duq.edu/academics/schools/nursing/newborn-assessment/skin

كلية التمريض
SCHOOL OF NURSING

Common Variations

كلية التمريض
SCHOOL OF NURSING

Common Variations

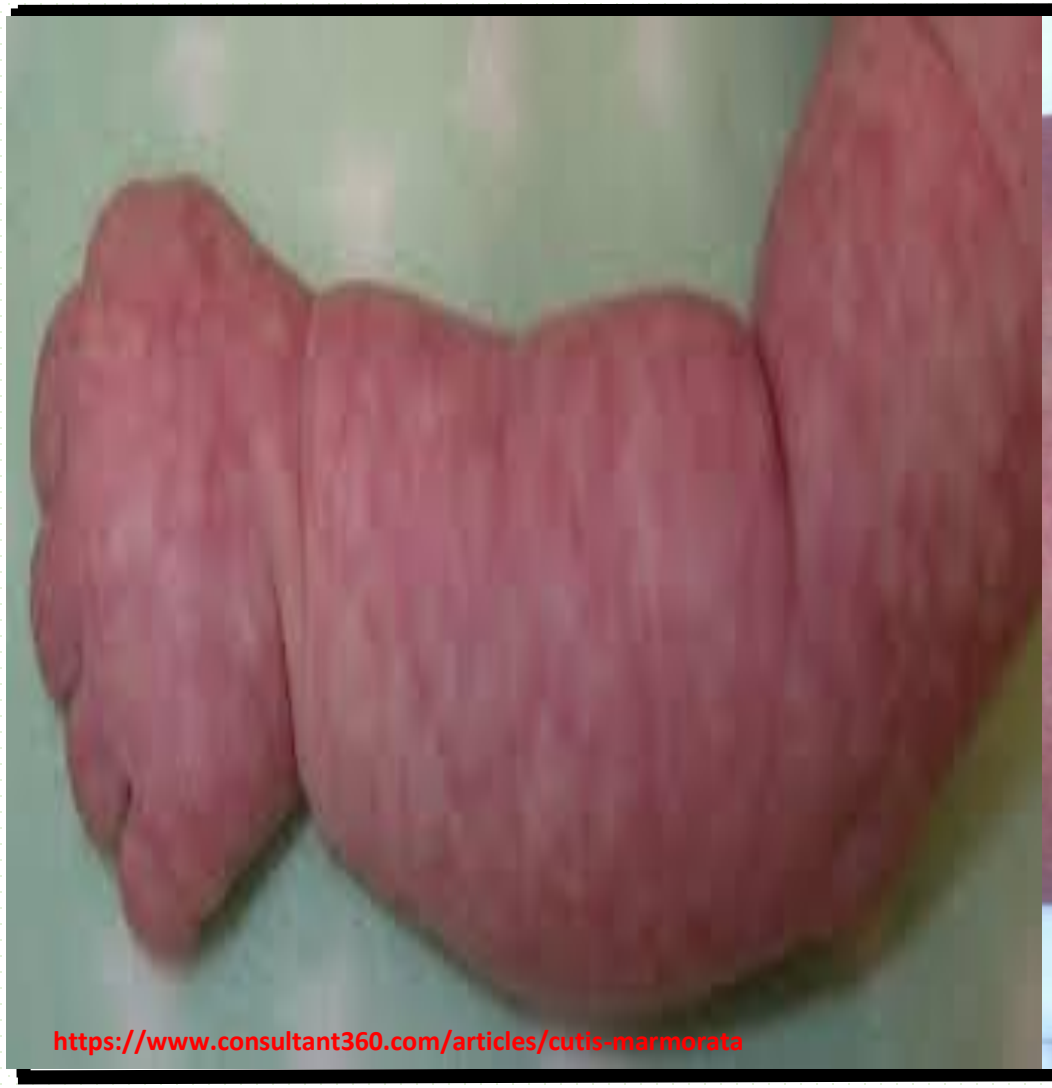

https://www.consultant360.com/articles/cutis-marmorata

https://www.pediatriconcall.com/spot-diagnosis/neonate-with-marbled-skin-appearance/205

كلية التمريض
SCHOOL OF NURSING

Common Variations

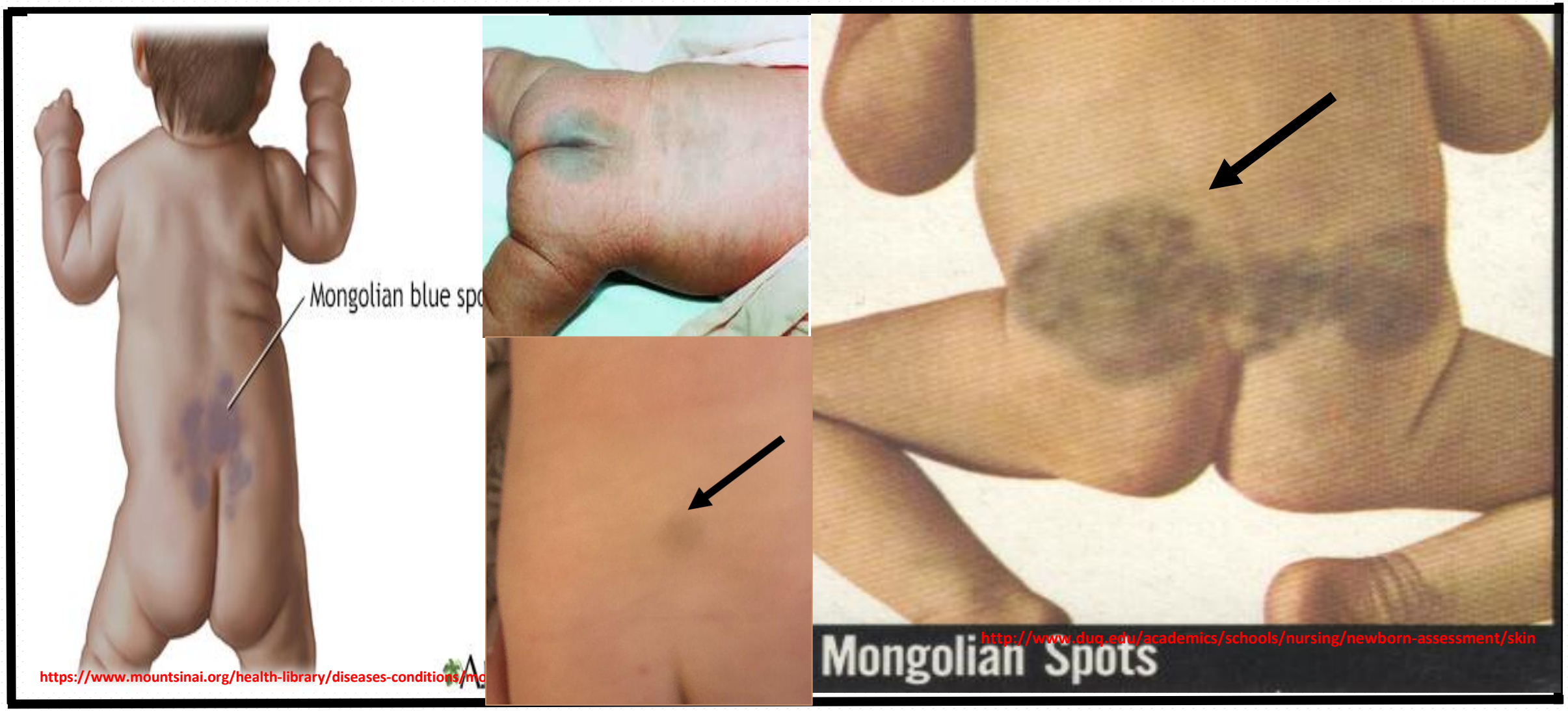

كلية التمريض
SCHOOL OF NURSING

Vernix caseosa

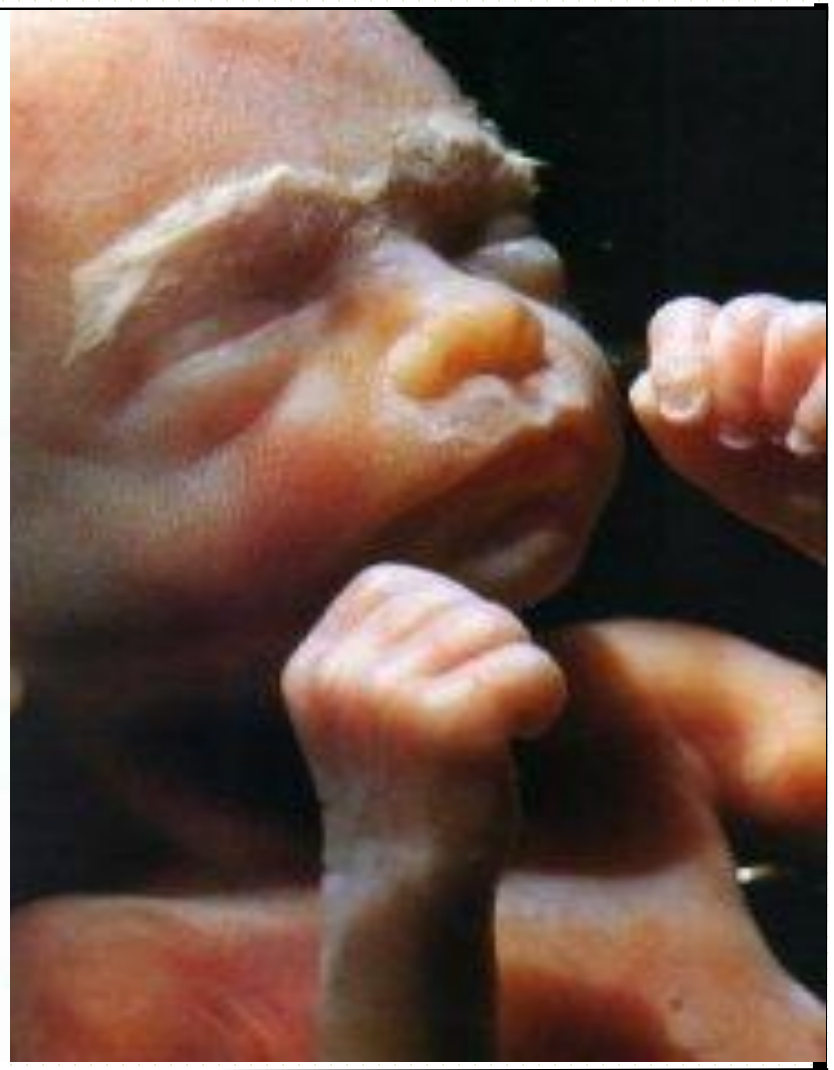

http://www.duq.edu/academics/schools/nursing/newborn-assessment/skin

Lanugo hair

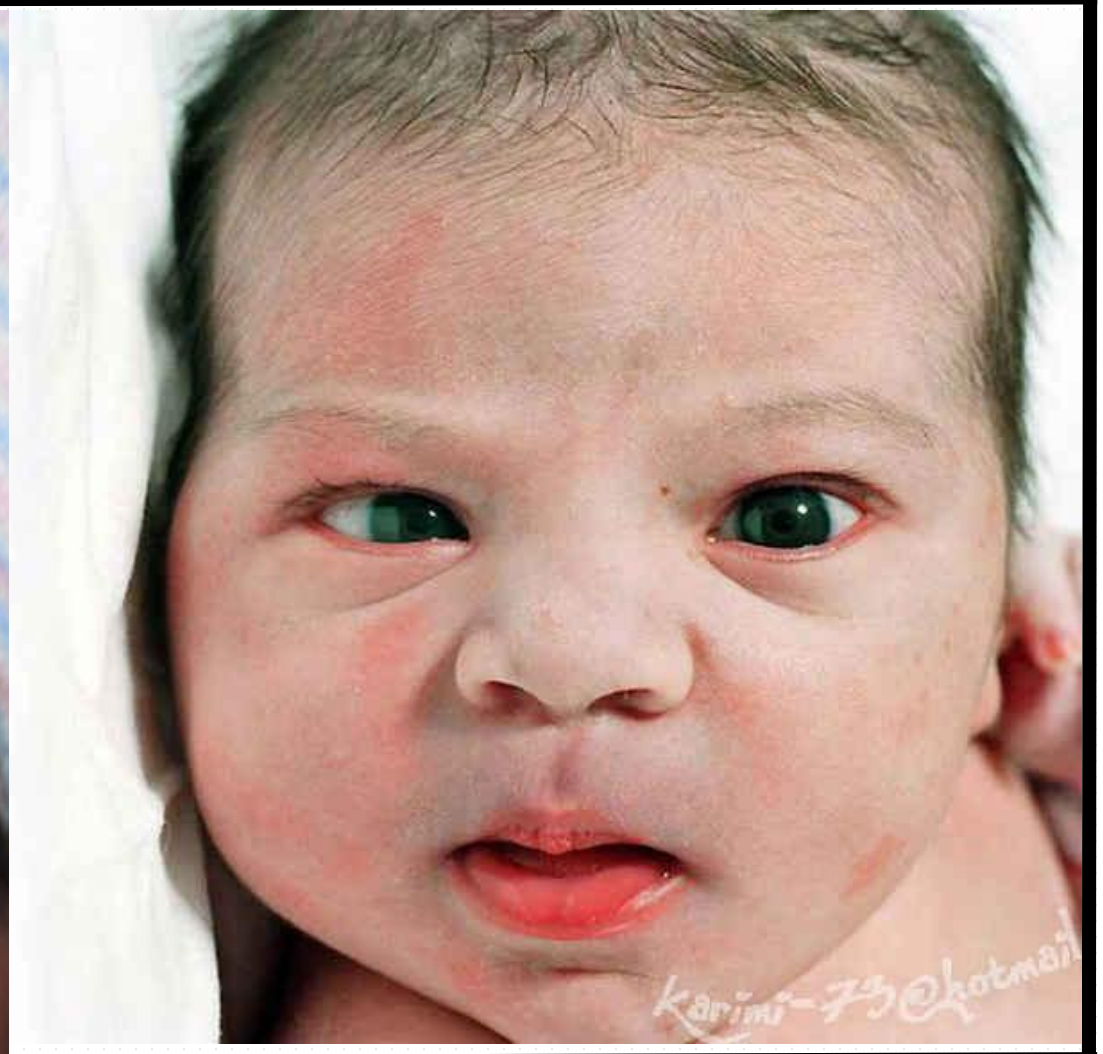

https://www.healthline.com/health/lanugo

Muscle Tone

FIG 8-7A Head control in an infant. **A,** Inability to hold the head erect when pulled to sitting position. **B,** Ability to hold the head erect when placed in ventral suspension.

All Elsevier items and derived items © 2013, 2009, Mosby, Inc., an imprint of Elsevier Inc.

Muscle Tone

FIG 8-7B Head control in an infant. **A,** Inability to hold the head erect when pulled to sitting position. **B,** Ability to hold the head erect when placed in ventral suspension.

All Elsevier items and derived items © 2013, 2009, Mosby, Inc., an imprint of Elsevier Inc.

Neurologic System

- At birth, the nervous system is incompletely integrated
- Primitive reflexes
- Autonomic nervous system is crucial in the newborn transition to life
- Myelination of the nerves follows a cephalocaudal and proximodistal progression

Omayah Nassar, PN, PhD, CLT
Suhaila Halasa, RN, PhD, CIMI, CPT

Neonatal Reflexes/Primitive

- Starts from intrauterine fetal life at the age of 28 weeks of gestation
- Most of the reflexes disappear normally at the age of 3-4 months after birth
- One reflex disappears at the end of the first month of life → Dance
- One last for ever → Red eye reflex
- One changes its response → Babinski

Omayah Nassar, RN, PhD, CPT
Sumaila Halasa, RN, PhD, CIMI, CPT

Neonatal Reflexes/Primitive

FIG 8-8A A, Plantar or grasp reflex. **B,** Babinski reflex. 1, Direction of stroke. 2, Dorsiflexion of big toe. 3, Fanning of toes.

A, From Zitelli BJ, Davis HW: *Atlas of pediatric physical diagnosis*, ed 5, St. Louis, 2007, Mosby.

Neonatal Reflexes/Primitive

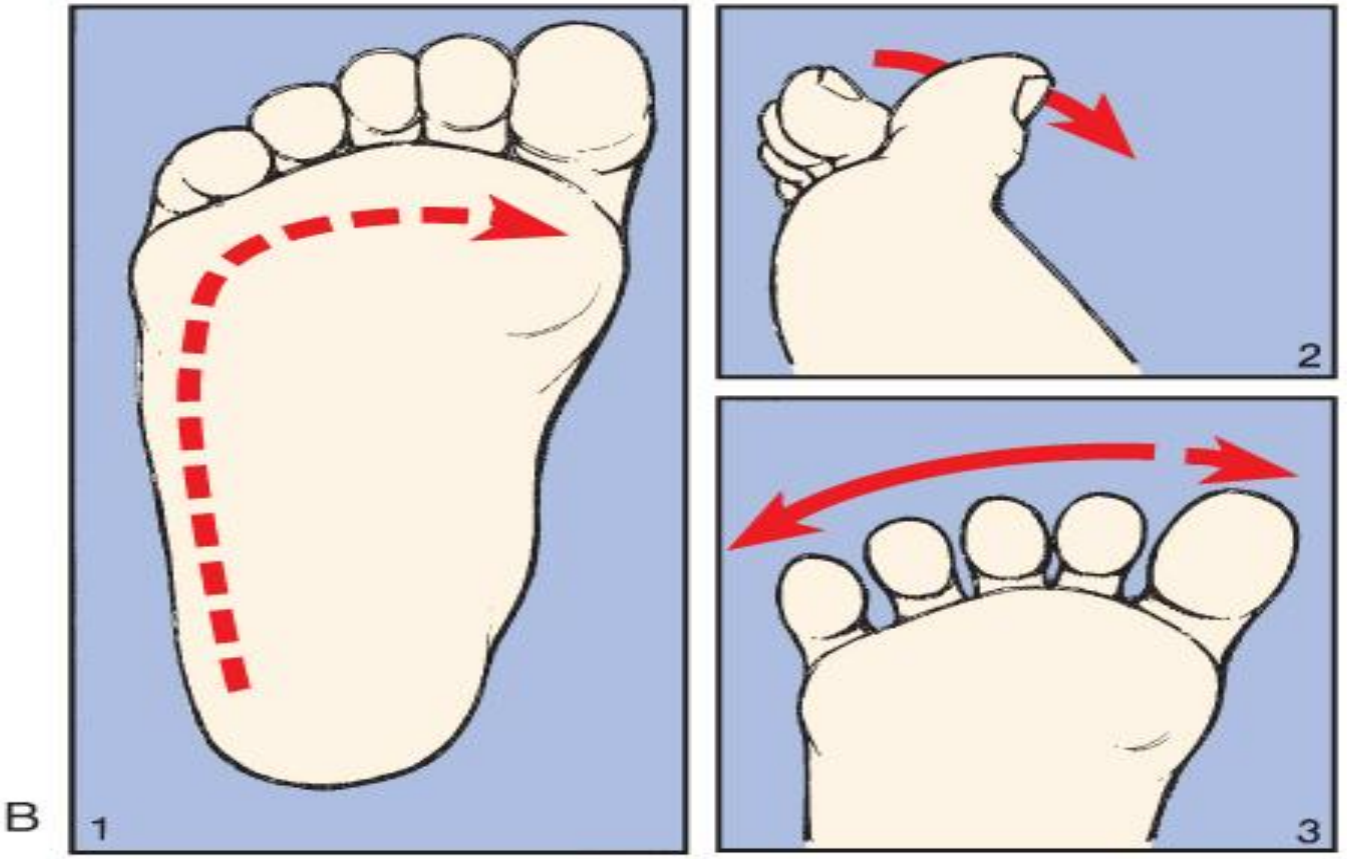

FIG 8-8B A, Plantar or grasp reflex. **B,** Babinski reflex. 1, Direction of stroke. 2, Dorsiflexion of big toe. 3, Fanning of toes.

A, From Zitelli BJ, Davis HW: *Atlas of pediatric physical diagnosis*, ed 5, St. Louis, 2007, Mosby.

Neonatal Reflexes/Primitive

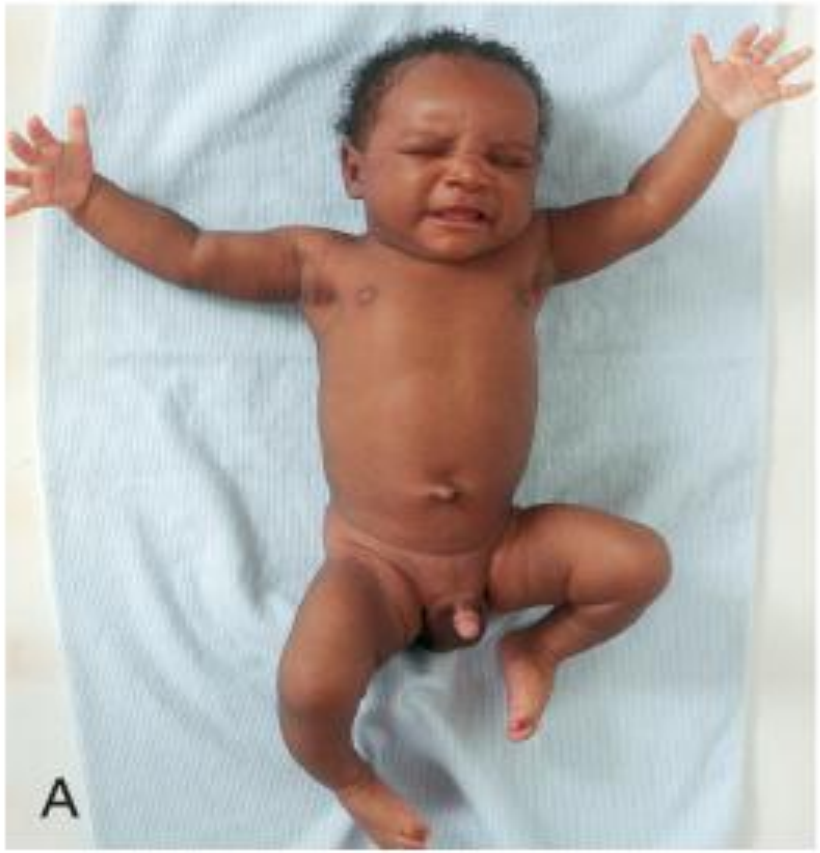

FIG 8-9A A, Moro reflex. **B,** Tonic neck reflex. **C,** Dance reflex. **D,** Crawl reflex.

Courtesy Paul Vincent Kuntz, Texas Children's Hospital, Houston.

Neonatal Reflexes/Primitive

FIG 8-9B A, Moro reflex. **B,** Tonic neck reflex. **C,** Dance reflex. **D,** Crawl reflex.

Courtesy Paul Vincent Kuntz, Texas Children's Hospital, Houston.

Neonatal Reflexes/Primitive

FIG 8-9C A, Moro reflex. **B,** Tonic neck reflex. **C,** Dance reflex. **D,** Crawl reflex.

Courtesy Paul Vincent Kuntz, Texas Children's Hospital, Houston.

Neonatal Reflexes/Primitive

FIG 8-9D A, Moro reflex. **B,** Tonic neck reflex. **C,** Dance reflex. **D,** Crawl reflex.

Courtesy Paul Vincent Kuntz, Texas Children's Hospital, Houston.

Immune System

- Skin and mucous membranes are **the first line** of defense from invading organisms
- **Second line** of defense is cellular elements of the immunologic system (neutrophils, eosinophils, lymphocytes)

Omayah Nassar, PN, PhD, CPT
Suhaila Halasa, RN, PhD, CIMI, CPT

Defenses Against Infection

- **The first line** of defense is skin & mucous membranes

- **The second line** of defense is cellular elements of immunologic system:

  - Neutrophils & monocyte → phagocytes for foreign agent
  - Eosinophils → phagocytes foreign protein
  - Lymphocyte (T&B cells) → converted to monocyte & antibody

Omayah Nassar, RN, PhD, CPT
Suhaila Halasa, RN, PhD, CIMI, CPT

Immune System

- **Third line** of defense is the formation of antibodies
  - Breast milk provides passive immunity (by means of immunoglobulin G [IgG]) against most major childhood diseases
  - **Natural immunoglobulin** production does not begin until **second month of life**

Omayah Nassar, PN, PhD, CPT
Suhaila M. Hasa, RN, PhD, CIMI, CPT

كلية التمريض
SCHOOL OF NURSING

Immune System

Immunoglobulin:

- **IgG:** **crosses the placenta**, it is transferred primarily during the 3rd trimester of pregnancy
- **IgM:** **Does not cross the placenta**
- **IgA**: **Does not cross the placenta, normally produced by the fetus in utero**

Omayah Nassar, PhD, CPT
Suhaila Halasa, RN, PhD, CNM, CPT

Immune System

Immunoglobulin:

- **IgG: crosses the placenta**, it is transferred primarily during the 3rd trimester of pregnancy

  - New-borns have immunity to DT, smallpox, measles, mumps, and some viral and bacterial diseases.

  - Immunity against common viral infections (measles) may last 4-8 months, whereas **immunity to certain bacteria disappear within 4-8 weeks**

Ohoud Nassar, PN, PhD, CPT
Suhaila Hamsa, RN, PhD, CHN, CPT

Immune System

- **Active acquired immunity**:

  When the pregnancy woman forms antibodies in response to illness or immunization

- **Passive acquired immunity:**

  When IgG antibodies are transferred to the fetus in utero

Omayah Nassar, RN, PhD, CPT
Sumaila Halasa, RN, PhD, CIMI, CPT

Immune System

- **IgM: Does not cross the placenta**

  - Most or all of it is produced by the fetus at 10-15 weeks' gestation

  -It is produced in response to blood group antigens, gram-negative, and some viruses in the expectant mother

  - Elevated levels of IgM at birth may indicate placental leaks or **IUI** (syphilis, toxoplasmosis, rubella, cytomegalovirus, herpesvirus, and group B streptococci.

Omayan Alassar, PN, PhD, CPT
Suhaila Halasa, PN, PhD, CNM, CPT

كلية التمريض
SCHOOL OF NURSING

Still we are talking about------

- The lack of available maternal **IgM** in the newborn accounts for the susceptibility to

  Gram- negative enteric organisms such as:

  Escherichia coli (E coli)

Lemayah Nassar, PN, PhD, CPT
Suhaila Halasa, RN, PhD, CIMI, CPT

Immune System

- **IgA**: Does not cross the placenta, normally produced by the fetus in utero

  - **Colostrum** is very high in the secretory form of IgA (Passive Immunity)

  - It is function are not fully understood.

  - It appears to provide protection mainly on secreting surfaces such as: resp. tract, GIT, and eyes

  - New-born begins to produce secretory IgA in the intestinal mucosa about **4 weeks after birth**

Omayah Nassar, RN, PhD, CPT
Sundus Halasa, RN, PhD, CIMI, CPT

Immune System

To conclude this part:

The newborns start to produce their own Ig after the 2 month of life

Omayeh Nassar, PN, PhD, CPT
Suhaila Halasa, RN, PhD, CIMI, CPT

Sensory Functions

- Smell
- Taste
- Touch

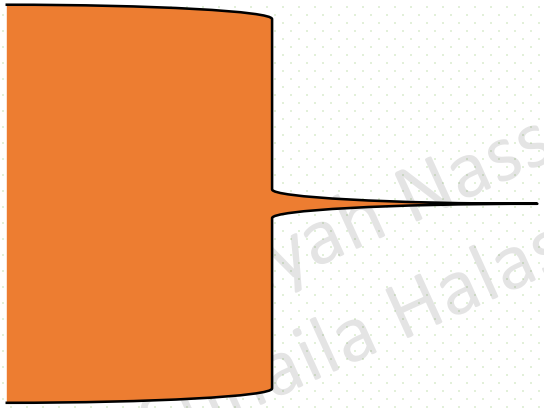

able to perceive and react

Suhaila Halasa, PhD, CIMI, CPT

Development of Senses

Vision:

- At birth, the eye is structurally incomplete
- Ciliary muscles limiting ability to accommodate and focus on an object but can follow object 20 cm
- Pupils react to light
- Blink reflex is responsive to a minimal stimulus.

Omayah Nassar, PN, PhD, CPT
Suhaila Halasa, RN, PhD, CIMI, CPT

Development of Senses

Vision:

- Corneal reflex is activated by a light touch.
- Tear glands usually do not begin to function until 2-4 weeks.
- Infant demonstrate visual preference, medium color (yellow, green, pink). Over bright (red, orange, blue) or dim color. Black and white contrasting patterns

Omayah Nassar, MN, PhD, CPT
Suhaila Halasa, RN, PhD, CIMI, CPT

Development of Senses

Hearing:

- Starts at 28 week's gestation
- Is similar to that of adults after amniotic fluid is drained
- Early sensitivity to human voices (not speech)
- The internal &middle ear are large at birth , but external canal is small (wide & short).

- **Startle reflex**

Omayah Nassar, RN, PhD, CPT
Suhaila Halasa, BN, PhD, CIMI, CPT

كلية التمريض
SCHOOL OF NURSING

Development of Senses

Smell:

- Newborn reacts to strong odor such as alcohol by turning their heads away
- Breast-fed infant can smell breast milk, maternal adores are believed to influence the attachment process & successful breast-feeding

Omayah Nassar, MN, PhD, CPT
Suhaila Halasa, RN, PhD, CIMI, CPT

Development of Senses

Taste:

- Newborn is able to distinguish between tastes and elicit by facial reflexes
- During childhood, the taste buds are distributed mostly on the tip of the tongue.
- **Gastro Facial Reflex**

Omayah Nassar, RN, PhD, CPT
Suhaila Halasa, RN, PhD, CWL, CPT

Development of Senses

Touch:

- At birth, the infant can perceive a tactile sensation in any part of the body; face (mouth), hands, soles, most sensitive

Omayah Nassar, RN, PhD, CPT
Suhaila Halasa, RN, PHD, CIMI, CPT

Holding vs Not Holding

https://www.articlecube.com/helping-dads-bond-babies

https://www.novabirthpartners.com/infant_massage.html

Infant Massage

Calendula Oil

Castor Oil

Chamomile Oil

Sunflower Oil

Almond Oil

Mustard Oil

Olive Oil

Sesame Oil

Tea Tree-Oil

Coconut-Oil

https://www.momjunction.com/articles/oils-good-baby-skin_0047136/#gref

BENEFITS OF INFANT MASSAGE FOR BABIES

RELIEF OF

- Can help with reducing gas, constipation, digestive cramps, and colic
- can relive growing pains, muscular tension, and teething discomfort
- can help to remove excess mucus
- Relieves physical and psychological tension
- reduces sensitivity to touch

STIMULATION

- stimulates language development and improved learning ability
- muscular development and tone
- stimulated healthy eliminations through the digestive tract
- Stimulates all systems of the body: circulatory, digestive, hormonal, immune, lymphatic, nervous, respiratory, and vestibular (coordination/balance)
- promotes mind and body awareness

INTERACTION

- Promotes bonding, secure attachment, and one-on-one quality time.
- Nurtures the feelings of love and respect
- helps develop tolerance and empathy
- develops pre-language communication skills
- teaches nurturing touch

RELAXATION

- Improved SLEEP patterns
- Regulation of behavioural states/self regulation
- reduction of stress hormones cortisol and norepinephrine which means reduced stress levels
- increase in relaxation hormones oxytocin, serotonin, and dopamine.
- reduced hypersensitivity and hyperactivity
- promotes the enjoyment of "quiet time"

pure love
INFANT MASSAGE

And so much more...

https://pureloveinfantmassage.com/blog/

Information sourced from IAIM.net

كلية التمريض
SCHOOL OF NURSING

Thank You

Omayan Nassar, PN, PhD, CPT
Suhaila Halasa, RN, PhD, CIMI, CPT